

*Original Research Article*

# Do matrix metalloproteinases have effects on transcarpal ligamentum hypertrophy in carpal tunnel syndrome?

Abdullah Talha SIMSEK<sup>1</sup> and Numan KARAARSLAN<sup>2\*</sup>

Abstract

<sup>1</sup>M.D. Namik Kemal University School of Medicine, Department of Neurosurgery, 59100, Tekirdag, Turkey.

<sup>2</sup>Assist. Prof. M.D.; Namik Kemal University School of Medicine, Department of Neurosurgery, 59100, Tekirdag, Turkey.

\*Corresponding Author's E-mail: [numikara@yahoo.com](mailto:numikara@yahoo.com)  
Pbx: +9028 2250 5500

Co-author's E-mail: [simsektalha@hotmail.com](mailto:simsektalha@hotmail.com)

It is known that matrix metalloproteinases (MMPs) play a role in the physiopathological cycle of different tissues. In this study, it was aimed to investigate whether the MMPs in the stromelysin and collagenase groups were the main determinant in the carpal tunnel syndrome. In this prospective study, the cases with carpal tunnel syndrome (CTS), which met also inclusion criteria, were evaluated immunohistopathologically. The alpha significance value was accepted as  $<0.05$ , and the results were evaluated at a 95% confidence interval. There was no statistically meaningful correlation observed between the operating hand electromyography (EMG) results and the MMPs expressions when examining MMPs staining patterns ( $p>0.05$ ). However, it was remarkable that the expression of these three enzymes was positively correlated with CTS. We believe that the data obtained from this study, in which the MMPs enzyme family has been evaluated in carpal tunnel syndrome, will have an important place in future studies in which these and similar pathologic treatments will be investigated.

**Keywords:** Carpal tunnel syndrome, matrix metalloproteinases, transverse carpal ligament.

**Abbreviations**

**BMI:** Body mass index; **CTS:** Carpal tunnel syndrome; **DM:** Diabetes mellitus; **ECM:** Extracellular matrix; **EMG:** Electromyography; **MMP:** Matrix metalloproteinases; **MRI:** Magnetic resonance image; **TCL:** Transverse carpal ligamentum; **TGF- $\beta$ 1:** Transforming growth factor beta-1.

## INTRODUCTION

The carpal tunnel syndrome (CTS) frequently encountered, is one of the most common peripheral entrapment neuropathies. A variety of causes that may be given rise to CTS have been reported before. However, in most of the patients, the exact cause and pathogenesis of CTS are unclear (Deskur et al., 2014). In the literature, there are many conservative treatment

options recommended for treatment of mild and initial stage cases of CTS, including particularly the wrist splint in a neutral position, using the non-steroidal anti-inflammatory drug, local injection of steroids, iontophoresis, B6 and B12 vitamin complexes, chiropractic and/or physical rehabilitation (Wolny, 2017; Lim et al., 2017). However, the effectiveness of the

conservative treatment methods for patients with CTS, associated with flexor tenosynovitis is still controversial (Mackinnon et al., 2011; Canale et al., 2012; Spinner et al., 2003). Apart from the conservative treatment options, in moderate cases, the surgery is suggested to provide the cure of CTS by performing decompression. In severe cases, the treatment modalities that are recommended by considering the etiology of disease are as follows: a) removal of pressure in Colles' fracture b) surgical synovectomy in rheumatoid arthritis c) surgical release (Mackinnon et al., 2011; Canale et al., 2012; Spinner et al., 2003; Huisstede et al., 2017).

Diverse surgical techniques have been proposed to release transverse carpal ligament (TCL), to decompress the intra-cutaneous pressure without causing damage on the median nerve, to increase the channel volume and to remove the pressure on the median nerve (Mackinnon et al., 2011; Canale et al., 2012; Spinner et al., 2003; Huisstede et al., 2017). These surgical techniques include; the open surgical technique with standard incision, mini-open surgical technique, and endoscopic surgical technique. However, the mentioned surgical techniques may not lead to desired results, particularly due to the development of the surgical complications such as motor branch damage, the scar tissue development superficial Palmar arch and the median nerve injury (Gibbons, 2015; Kokkalis et al., 2016; Lee et al., 2014; Cheung et al., 2017; Papatheodorou et al., 2015).

In this case, it has been started to be used molecular and/or immunohistopathological techniques to replace or to repair biological activities of the damaged cells and tissues by providing personalized cellular therapy (Akyuva et al., 2017). Among all these findings, the research of the MMPs, which is thought to play a vital role in the physiological states such as the tissue remodelling, morphogenesis, wound healing and normal developmental process and in the pathological states such as invasion of the tumour cell, angiogenesis, metastasis and in the certain disorders related to the connective tissue, skin, lung, cardiac muscle tissues and metabolism, have gained popularity.

It has been observed the increase in the effectiveness and the expression of the stimulated MMPs in various experimental disease model setup among the researches gained popularity (El-Salem and Ammari, 2006; Galis and Khatri, 2002). Depending on the stimulation, MMPs increase the cell proliferation and facilitate smooth muscle cell migration by breaking down the extracellular matrix (ECM) proteins such as collagen, gelatine, elastin, laminin, and proteoglycan (Yilmaz et al., 2013; Lockwood et al., 1998). In addition, there are some findings where it has been reported that MMPs have not expressed or have expressed slightly in normal, healthy and resting tissues (Chen et al., 2017; Liu et al., 2017; Hegewald et al., 2013; Kang et al., 2017; Burger et al., 2016; Ulrich et al., 2009; Hirata et al., 2005; Ulrich et al., 2003;

Karaarslan et al., 2016).

Yilmaz et al. (2013) reported in their study that the level of expression of the MMPs increased during the repair and regeneration of any tissue. They also reported that MMPs were necessary for the regeneration of the connective tissue, even if they were trace amount in normal growth and development. It was also stressed that the importance of the MMPs in both the diseases directly linked to the inflammation, cancer, bones, cartilage tissue, the impaired collagen structure of the related tissues and many catabolic and anabolic processes such as matrix renewal (Ulrich et al., 2003; Karaarslan et al., 2016; Gokay et al., 2016).

In addition to that, it has been reported in the literature that MMPs play a significant role in several pathophysiologic cycles, including the reconstruction of the different tissues such as cartilage, remodelling of the bones, wound healing, angiogenesis, inflammation, apoptosis and development of immunoreaction (Ulrich et al., 2003; Karaarslan et al., 2016; Gokay et al., 2016).

However, when reviewing literature, it has not observed any study, having significant evidential value and performing on the human tissues, and where MMP-3, MMP -8 and MMP -13 have been evaluated immunohistochemically together with CTS and TCL functions.

Therefore, in this prospective study, it has been aimed to investigate the role played by MMP-3/ stromelysin, MMP-8/callogenesis, and MMP-13/callogenesis in the development of CTS by analysing their stain patterns in TCL. In this way, it has been aimed to give insight into the CTS, pathophysiology of which remains still unknown and which has been explained by theories such as microvascular failure, mechanical pressure and vibration (Galis et al., 2002).

## MATERIALS AND METHODS

Informed consent was obtained from the patients to work on their tissues. The operations were carried out by the same surgeon. The immunohistopathological analyses were performed by the same researcher to minimize experimental errors. All analysis was repeated three times.

The study was carried out with the approval of Namik Kemal University Medical Faculty, Local Ethics Board (2017/55/05/04).

### Materials

The functions of the muscle and peripheral nerves were measured by recording their electrical activities with EMG (NihonKodhen Corporation Tokyo, Japan (#80270) and magnetic resonance image (MRI; GE HEALTHCARE-

OPTIMA MRA360 1.5 Tesla). Immunohistochemical staining was carried out by using Bond Polymer Refine Detection Kit with LeicaBond, Max Automated Immunohistochemistry / *in-situ* hybridization (Leica Bond-Max Fully automatically IHC&ISH). The antibodies of MMP-3 (CAS# NB100-91878), MMP-8 (CAS# NBP2-17316), and MMP-13(CAS# NBP2-45887), Rabbit Polyclonal Antibody, Novus, Novus Biologicals, Littleton, CO 80120 used in the staining process were procured from U.S.A.

The slide we used in this study was Isolab (CAS# LB.IS.076.02.012) and the entellan using to cover the slide is Aqueous-mount, ScyTek Laboratories, Utah, USA.

## Methods

### Study design

Detailed anamnesis of the patients was taken and, the patients diagnosed with CTS (n=40) after physical and neurological examination and/or upper extremity EMG and hand MRI were operated on. The resected tissues during surgery were analysed histopathologically with the help of immunohistochemical stains for the expression of MMP-3, MMP-8, and MMP-13.

### Case Selection Criteria

At the beginning, the study's scope consisted of cases (n=67) with complaints related to the involvement of the sensory axons of the median nerve.

Biochemical and hormonal parameters of the patients having the following symptoms detected after physical examination were examined; a) One of the most common symptom is burning pain associated with tingling and numbness in the distribution of median nerve distal to the wrist. The part of the hand affected is the thumb, index and middle fingers, and the radial half of the ring finger b) Patients are often awoken by pain in the middle of the night and report hanging their hand out of bed or shaking it vigorously to relieve their pain c) Patients may also complain of pain expanding to the forearm, and the shoulder d) a feeling of clumsiness and weakness in the affected hand that often worsens with activity is one of less common symptom.

Even though most cases of CTS are of unknown cause, or idiopathic, multiple blood tests were carried out for the differential diagnosis of the secondary causes. These blood tests included glucose test, erythrocyte sedimentation rate test, antinuclear antibody test, thyroid function test, and specific tests concerning the diseases stemming from uric acid level and storage diseases arising from metabolic causes.

The patients were taken to the EMG laboratory to make further evaluations after biochemical laboratory tests. The patients having following symptoms were excluded from the scope of study: a) the mild cases (n=10) where it was observed median nerve distal antidromic sensory latency, median nerve distal orthodromic sensory latency, palmar sensory latency, and the cases where it was observed that the sensory nerve action potential amplitude decreases below normal level b) the moderate cases (n=4) where it was observed prolonged median nerve distal motor latency c) the cases where it was observed Raynaud Phenomenon (n=1), skin drying on nerve distribution area (n=2), swelling (n=2), colour changes (n=3) and the other symptoms related to the autonomic nervous system involvement (n=2).

The patients treated with azathioprine (Aroori et al., 2008) and cyclosporine (de Boer et al., 2013) were excluded from the scope of the study (n=3) due to the breakdown of the MMPs (Kim et al., 2015) by azathioprine and cyclosporine and the inhibition of the MMPs by statins.

The severe cases having the following symptoms (n=40), which were detected after EMG examination, were included in the scope of the study; a) the cases where it was observed the absence of the sensory action potential, and the cases where it was also observed that the response of the thenar motor is “-” status b) the cases where it was observed noticeable reduction in amplitude, prolonged distal latency and partial denervation detected through thenar EMG.

### Electrodiagnosis and MRI

EMG Analysis; EMG test was performed in all cases included in the study to distinguish the cases thought to be CTS from cervical spondylosis, 3-brachial plexus lesions, peripheral polyneuropathies, thoracic-outlet syndrome, multiple sclerosis, cervical (C5-6) radiculopathies and trapping neuropathies in other areas of the median nerve, and to measure the severity of the median nerve damage.

The reports issued by the American Society of Electrodiagnostic Medicine, the American Academy of Neurology and the American Academy of Physical Medicine and Rehabilitation were taken as references while performing the mentioned measurement. The measurement of the conduction rate to determine the distal proximal sensory ratio was performed by calculating the ratio between the wrist conduction rate measured from the third finger and the palm-wrist conduction rate measurements. Considering this result, CTS was diagnosed. Sensory conduction was measured in the distal wrist where it was seen 13-14 centimetres CTS symptoms. The measured values were compared

with the sensory conduction of the other nerves innervating the zones adjacent to the symptoms (Li Pi Shan et al., 2016).

In radiological examination; thin-section computed tomography of the wrist was not performed since it gave insufficient information about median nerve and soft tissues. Instead, MRI was performed as it showed effectively musculoskeletal system diseases and soft tissue problems with high resolution and multiplanar cross-sectional imaging. Dynamic MRI of the wrist was also taken as it gave sufficient information about following fields: a) it shows median nerve compression at the level of the pisiform bone when the wrist is in flexion, and at the level of the pisiform and the hook of hamate when the wrist is in extension b) it shows clearly the carpal tunnel's boundaries, dimensions, anatomy, and the developing oedema c) it also shows the tumoural tissues resulting from bone tissue adjacent to the carpal tunnel and calcified lesions as well (Chen et al., 1997).

### Surgical Technique

After preoperative evaluations the patients underwent an operation. The patients were placed in the supine position and the symptomatic hand antisepsis was ensured with 10% polyvinyl pyrrolidone iodine solution. The symptomatic extremity was placed on the mayo table as being parallel to the ground. The hand was positioned so that the palm could remain in the up position and it was covered in sterile manner. Approximately 1-1.5 cm incision line was marked longitudinally along the imaginary line passing the radial edge of the fourth finger, starting from the Kaplan cardinal line, near the flexor retinaculum. After having been diluted with 10 ml of 0.9% isotonic sodium chloride solution, a total of 4 ml of lidocaine and an anaesthetic agent containing hydrochloric acid salt of epinephrine for local anaesthesia were administered along the line to be incised.

After providing local anaesthesia, it was passed into the skin and under the skin by performing surgical incision. TCL was identified and incised with the help of surgical dissection scissors. Median nerve was identified, and the decompression was confirmed. The tissue samples were taken. After controlling the bleeding, the skin and under skin were closed properly by suturing.

### Immunohistochemical staining and staining grading

In TCL samples resected from patients with CTS after surgical operations; 4µm sections were taken from paraffin blocks to analyze immunohistochemically MMP-

3, -8 and -13 expressions. These sections were transferred to slides previously coated with poly-lysine. It was incubated for 132 hours at 47°C. Subsequently, the samples were subjected to sequential washing and fixation with alcohol, deionized water, in order to be able to perform histopathological evaluations. A specific polymer horseradish peroxidase for rabbit primary antibodies was added to each MMP enzyme expression for the purpose of immunostaining with Haematoxylin and Eosin stain. The slides detached from the device were dried and covered with entellan.

Immunohistochemical staining of all cases were evaluated separately. This evaluation was conducted by enlarging and scanning all the fields at x400. In all of the cases with staining patterns, if there was a diffuse mild-moderate staining for MMP-3, -8 and -13 enzymes, the staining pattern was evaluated as being positive. In cases with no staining, the staining pattern was evaluated as being negative.

### Statistical analysis

Number Cruncher Statistical System 2007 Statistical Software Program was used. In the evaluation of the obtained data, descriptive statistics were given as mean ± standard deviation, median and frequency ratio. The Mann Whitney-U test was used in the inter-group comparisons of the non-normally distributed parameters of the data obtained from the cases included in the study. Fisher's Exact and Fisher-Freeman Halton tests was used to compare qualitative data. The alpha significance value was accepted as <0.05, and the results were evaluated at a 95% confidence interval.

### RESULTS

The demographic data of the cases (Table 1) and the test results of the wrist (Table 2) were reported. When the EMG results of the operating hand were examined; it was observed that the percentages of cases with severe, moderate-severe, moderate, mild and normal CTS were 17.5, 12.5, 62.5, 5 and 2.5 respectively. There was no statistically meaningful relationship observed among body mass index (BMI), diabetes mellitus (DM), arterial hypertension (HT), rheumatoid arthritis and hypothyroidism rates and MMP-3, -8 and -13 staining patterns ( $p > 0.05$ ). There was no statistically meaningful correlation observed between the operating hand EMG results and the MMPs expressions when examining MMPs staining patterns ( $p > 0.05$ ). However, it was remarkable that these three enzyme expressions

**Table 1.** Distributions of demographic and descriptive properties.

Age (Year)	Minimum-Maximum (Median)	31-81 (57.5)
	Mean±SD	55.60±11.38
Gender (Frequency)	Female	38 (95%)
	Male	2 (5%)
Length (cm)	Minimum-Maximum (Median)	142-175 (160)
	Mean±SD	160.33±7.5
Weight (kg)	Minimum-Maximum (Median)	50-120 (75.5)
	Mean±SD	77.5±14.40
	Minimum-Maximum (Median)	20.88-46.88 (29.55)
	Mean±SD	30.24±5.79
BMI (kg/cm <sup>2</sup> )	Normal Minimum-Maximum (Median)	6 (15.0)
	Morbid-obesity Minimum-Maximum (Median)	17 (42.5)
	Obese Minimum-Maximum (Median)	17 (42.5)
Accompanying diseases (Frequency)	-	24 (60.0%)
	+	16 (40.0%)
Type of accompanying diseases (Frequency)	DM	8 (20.0%)
	Hypertension	9 (22.5%)
	Rheumatoid arthritis	7 (17.5%)
	Hypothyroidism	2 (5.9%)

**Table 2.** Distribution of CTS cases, according to evaluation of MRI and EMG examinations.

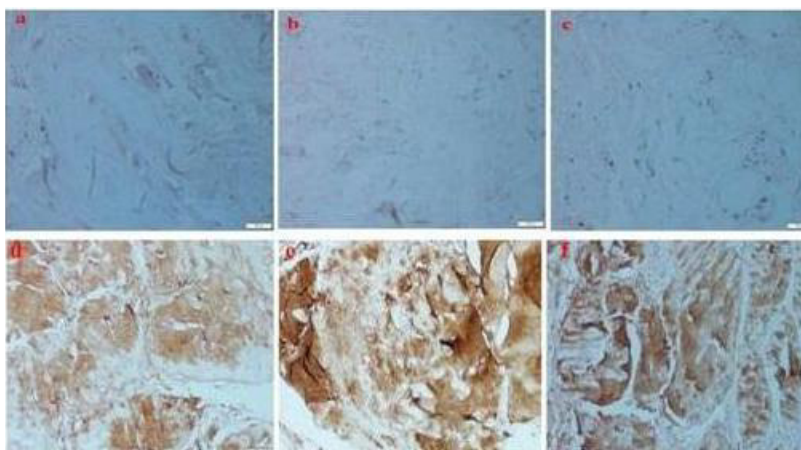
Dominant hand EMG (Frequency)		
Right hand	39 (97.5%)	
Left hand	1 (2.5%)	
Operated hand(Frequency)		
Severe	7 (17.5%)	
Medium severe	5 (12.5%)	
	Medium	25 (62.5%)
	Mild	2 (5.0%)
Normal	1 (2.5%)	
Healthy hand(Frequency)		
Severe	4 (10.0%)	
Medium severe	1 (2.5%)	
Medium	25 (62.5%)	
Mild	2 (5.0%)	
Normal	1 (2.5%)	
Unknown	7 (17.5%)	

**Table 3.** Distribution of MMP staining measurements in CTS-diagnosed cases.

MMPs	The frequency of staining positivity	The frequency of staining negativity
MMP-3	28 (68.3%)	13 (31.7%)
MMP-8	27 (65.9%)	14 (34.1%)
MMP-13	31 (75.6%)	10 (24.4%)

were positive in most cases with CTS (Table 3, Fig. 1).  
The cases without staining were 15%, while the

frequency of the cases staining with one, two and three markers was; 15%, 17.5% and 52.5% respectively.



**Figure 1.** Histopathological examination of TCL under x400 magnification with the help of light microscope; a: MMP-3 b: MMP-8 and c: MMP-13, the letters depict negative staining patterns of the mentioned enzymes, d: MMP-3 e: MMP-8 and f: MMP-13, the letters depict positive staining patterns of the mentioned enzymes.

## DISCUSSION

Reviewing the literature, the importance of tumor necrosis factor alpha, which is included in the proinflammatory cytokines, and of the harmful enzymes such as matrix MMPs are emphasized in the catabolic cycle of many tissues pertain to the musculoskeletal system, and particularly cartilaginous tissue. In addition, it has been reported that the Smad complex, which is included in a family of intracellular proteins, has been activated due to the overexpression of the Transforming Growth Factor beta-1 (TGF- $\beta$ 1) in arthritic joints by interacting genetically with MMPs in the cell. It has been also reported that activated SMAD protein complexes provide gene regulation that works to protect cells like chondrocyte by interacting directly or indirectly with the precursors of MMPs thanks to the transcription factors (Spinner et al., 2003).

In the literature; there are studies investigating whether MMPs play a role in many physiopathological cycles (Chen et al., 2017; Liu et al., 2017; Hegewald et al., 2013; Kang et al., 2017; Burger et al., 2016; Ulrich et al., 2009; Hirata et al., 2005; Ulrich et al., 2003; Karaarslan et al., 2016; Gokay et al., 2016) or studies investigating the relationship between CTS and age, obesity and thyroid gland disorders (Chammas et al., 2014; Werner et al., 1994; Gamstedt et al., 1993; El-Salem et al., 2006; Kececi et al., 2006; Çakır et al., 2003; Kumar et al., 2012; DeLeoandYeziarski et al., 2001; Gharagozlian et al., 2009).

However, there are only three researches with high evidential value in which CTS is directly associated with MMPs (Kang et al., 2017; Burger et al., 2016; Hirata et

al., 2005). When examining the full texts of these three researches, it has been observed that no investigations have been carried out to evaluate the enzymes MMP-3, -8 and -13.

In this study, it was aimed to investigate the roles of MMP-3, -8 and -13 in the development of CTS at immunohistopathological level by examining their staining patterns in TCL. Therefore, we believe that the data obtained in this study can provide strong contributions to the literature.

It has been reported in the literature that the incidence of CTS increases with age in men and may increase with menopause in women (Chammas et al., 2014). Median nerve neuropathy was found in 261 of 949 patients about whom median and ulnar nerve motor and sensory conduction studies in the upper right limbs were carried out. Among these patients, the proportion of obese (BMI > 29) to those of weak (BMI < 29) was found to be 68.57% (Werner et al., 1994). It has been reported that there are CTS, Dupuytren's contracture, flexor tenosynovitis and range of motion restriction in 20% of diabetic cases, and a strong relationship between hand anomalies and DM (Gamstedt et al., 1993). In diabetic cases, it has been asserted that the increase in the level of the serum MMP-2 and 9 may play a role in peripheral neuropathy (DeLeoandYeziarski et al., 2001; Gharagozlian et al., 2009).

El-Salem et al. (2006) indicated that CTS was the most common neuromuscular pathology in thyroid disorders. There are some studies in which it is emphasized that demyelination due to hypothyroidism and axonal damage may occur. There are also some researches in which it is asserted that neuropathy is less

frequent and subclinical in hypothyroidism (Kececi et al., 2006; Çakır et al., 2003, Kumar et al., 2012).

In this research, the age range of the cases varied from 31 to 81 years ( $55.6 \pm 11.38$  mean  $\pm$  SD). Although 85% of the evaluated cases were overweight or obese, no statistically meaningful relationship was found between CTS and BMI or obesity.

In addition, in this research, it was observed that, in accordance with the literature, the cases with DM accompanying CTS were found to constitute 20% of the target population, whereas in contrast to the literature, there was no statistically meaningful relationship between hypothyroidism and CTS in the cases evaluated in this study.

Burger et al. (2016) studied the role of MMP-1, MMP-3, MMP-10 and MMP-12 enzyme variants in the pathophysiology of CTS and found no significant statistical relationship between these enzymes and CTS. In a study conducted by Hirata and colleagues, it was shown that the MMP-2's level increased in the cases with CTS. Pharmacological regulation of MMP-2 was reported to be beneficial in the treatment of the cases with idiopathic CTS (Burger et al., 2016).

Kang et al. (2017) used the adenovirus-relaxin (Ad-RLN-as therapeutic gene vector) and the adenovirus-lacZ marker gene to investigate the antifibrotic effect of *Relaxin* in sub synovial fibroblasts activated by TGF- $\beta$ 1. *In vitro*, sub synovial fibroblast cultures of non-adenoviral exposed samples were used as a control group.

In addition to the induction of collagen type I, III and IV gene expressions, alpha smooth muscle actin ( $\alpha$ -SMA) synthesis at the protein level, Smad2 phosphorylation and fibronectin were reported to be less synthesized than the control group. Moreover, they underlined that MMPs were significantly induced. It was asserted that this effect developed by reducing the expression of various ECM components such as Relaxin, fibronectin,  $\alpha$ -SMA and phosphorylated SMAD2 (Kang et al., 2017).

Burger et al. (2016) reported the involvement of the tendon and / or connective tissue in the studies where they investigated whether variants within MMP genes were associated with CTS in the etiology of the idiopathic CTS. They indicated that the deoxyribonucleic acid sequence variants in the genes encoding the structural components of collagen fibril, the basic structural unit of connective tissue, were associated with the modulation of the CTS risk. In addition, in their research, where they reported a vital role of the MMPs in the remodelling of the connective tissue, they emphasized that MMP-1, -3, -10, and -12 variants did not correlate with CTS.

Hirata et al. (2005) performed experiments to investigate the relationship between flexor tenosynovium pathology and its symptomatology because there were no correlation between the severity of CTS symptoms

and electrophysiology or nerve functions. For doing this, they recorded the duration of symptoms by evaluating preoperatively the severity of the symptoms through Likert scale in patients with CTS. They tested the flexor tenosynovium, arterial and connective tissue changes biopsied during surgery. In the research, where they used gelatin zymography and immunohistochemical methodologies to investigate the role of gelatinase in CTS, they emphasized that that MMP-2 was overexpressed and that intimal hyperplasia progressed rapidly between 4 and 7 months, leading to severe vascular narrowing. In the gelatin zymography results, they also reported that MMP-2 activity was negative over the course of the symptom but correlated positively with pain severity (Hirata et al., 2005).

In conclusion, in this first study in the literature, where the role of CTS or TCL in relation to MMPs has been investigated in a limited number of studies, the role of MMP-3, -8 and -13 in the development of CTS was compared and evaluated and, MMP-3, -8, -13 enzyme staining patterns and the specimens taken from TCL cases were examined.

The MMP-3 staining pattern was found to be positive in 67.5% (n=27) of all cases. However, the MMP-8 staining pattern was positive in 60% (n=24) of all cases. This ratio was found to be 75% (n=30) in MMP-13 enzyme. Although the relationships of MMP-3, MMP-8 and MMP-13 with TCL and CTS hypertrophy development were not statistically meaningful, it was remarkable that the mentioned rate were more positive in most of the CTS cases, especially in advanced, moderate-severe and moderate cases.

This study may have two limitations. First limitation of our study is that no comparison was made between patient and healthy tissues, it is not ethically possible to obtain healthy tissue from a healthy person. The second and the real limitation of this study is that the number of samples prepared in this study was low (n = 40), and the people from whom these samples were obtained had the same race.

## CONCLUSIONS

For the time being, even if researches on the surgical field MMPs are limited, it is likely that such researches will take place in the next few years, in many branches of research, including neurosurgery, to a significant extent. The use of the MMP enzyme family, being a potential therapeutic agent in the treatment of such diseases, is expected to gain importance in the personalized treatment of the patient thanks to the manipulation of MMP genes in the future. In addition to these, it should not be forgotten that such studies will provide data for new drug studies to provide the regulation of MMPs or for molecular studies at the experimental stage.

## ACKNOWLEDGMENTS

We are thankful to Medical Pharmacologist *Ibrahim YILMAZ* of the Istanbul Medipol University School of Medicine, Department of Medical Pharmacology for determining the exclusion criteria and edited the article and made suggested revisions for grammar, word choice, wordiness, awkward phrases, clarity, etc. as an independent individual. In addition, we would like to warmly thank *Prof. M.D. Nilda TURGUT* and *Prof. M.D. Aysun UNAL* of the Namik Kemal University School of Medicine, Department of Neurology, who performed independently EMG; to Assist. Prof. M.D. *Omer OZCAGLAYAN* of the Namik Kemal University School of Medicine, Department of Radiology; Assist. Prof. M.D., *Meltem OZNUR* of the Namik Kemal University School of Medicine, Department of Pathology, who performed independently radiological and pathologic evaluations.

## Competing Interests

The authors declare that they have no conflicts of interest with respect to the authorship and/or publication of this article.

## Funding

The authors received no financial support for the research and/or authorship of this article.

## REFERENCES

- Akyuva Y, Karaarslan N, Yilmaz I, Ozbek H, Sirin DY, Gurbuz MS, Kaya YE, Kaplan N, Ates O (2017). How Scaffolds, which are Polymeric Drug Delivery Systems Allowing Controlled Release, can be Tested in Human Primary Nucleus Pulposus and Annulus Fibrosus Cell Cultures? *Merit Res. J. Med. Med. Sci.* 5: 477-487.
- Aroori S, Spence RA (2008). Carpal tunnel syndrome. *Ulster Med J.* 77: 6-17.
- Burger MC, De Wet H, Collins M (2016). Matrix metalloproteinase genes on chromosome 11q22 and risk of carpal tunnel syndrome. *Rheumatol Int.* 36: 413-419.
- Canale ST, Beaty JH (2012). *Campbell's Operative Orthopaedics*, 12th ed. Philadelphia, PA: Elsevier Mosby. 55.
- Chammas M, Boretto J, Burmann LM, Ramos RM, DosSantos Neto FC, Silva JB (2014). Carpal tunnel syndrome- Part I (anatomy, physiology, etiology and diagnosis). *Rev Bras Ortop.* 49: 429-436.
- Chen P, Maklad N, Redwine M, Zelitt D (1997). Dynamic high-resolution sonography of the carpal tunnel. *AJR Am J Roentgenol.* 168: 533-537.
- Chen S, Luo J, Reis C, Manaenko A, Zhang J (2017). Hydrocephalus after Subarachnoid Hemorrhage: Pathophysiology, Diagnosis, and Treatment. *Biomed. Res Int.* 2017: 8584753.
- Cheung K, Klausmeyer MA, Jupiter JB (2017). Abductor Digiti Minimi Flap for Vascularized Coverage in the Surgical Management of Complex Regional Pain Syndrome Following Carpal Tunnel Release. *Hand (N Y).* 12: 546-550.
- Creemers EE, Cleutjens JP, Smits JF (2001). Matrix Metalloproteinase Inhibition After Myocardial Infarction: A New Approach To Prevent Heart Failure? *Circ. Res.* 89: 201-210.
- Çakır M, Samancı N, Balcı N, Balcı MK (2003). Musculoskeletal manifestations in patients with thyroid disease. *Clin. Endocrinol.* 59: 162-167.
- de Boer YS, van Gerven NM, de Boer NK, Mulder CJ, Bouma G, van Nieuwkerk CM (2013). Allopurinol safely and effectively optimises thiopurine metabolites in patients with autoimmune hepatitis. *Aliment Pharmacol. Ther.* 37: 640-646.
- DeLeo JA, Yezierski RP (2001). The role of neuroinflammation and neuroimmune activation in persistent pain. *Pain.* 90: 1-6.
- Deskur Z, Deskur A (2014). Zawadzki M. Influence of selected physical exercises to improve outcomes in patients operated for carpal tunnel syndrome in own material. *Centr. Eur. J. Sport Sci. Med.* 8: 47-51.
- El-Salem K, Ammari F (2006). Neurophysiological changes in neurologically asymptomatic hypothyroid patients: A prospective cohort study. *J Clin. Neurophysiol.* 23: 568-572.
- Galis ZS, Khatri JJ (2002). Matrix metalloproteinases in vascular remodeling and atherogenesis: The good, the bad, and the ugly. *Circ Res.* 90: 251-262.
- Gamstedt A, Holm-Glad J, Ohlson CG, Sunström M (1993). Hand abnormalities are strongly associated with the duration of diabetes mellitus. *J. Int. Med.* 234: 189-193.
- Gharagozian S, Svennevig K, Bangstad HJ, Winberg JO, Kolset SO (2009). Matrix metalloproteinases in subjects with type 1 diabetes. *BMC Clin Pathol.* 9:7.
- Gibbons CP (2015). Neurological complications of vascular access. *J Vasc Access.* 16: 73-77.
- Gokay NS, Yilmaz I, Komur B, Demiroz AS, Gokce A, Dervisoglu S, Gokay BV (2016). A Comparison of the Effects of Neuronal Nitric Oxide Synthase and Inducible Nitric Oxide Synthase Inhibition on Cartilage Damage. *Biomed. Res. Int.* 2016: 7857345.
- Hegewald AA, Zouhair S, Endres M, Cabraja M, Woiciechowsky C, Thomé C, Kaps C (2013). Towards biological anulus repair: TGF-β3, FGF-2 and human serum support matrix formation by human anulus fibrosus cells. *Tissue Cell.* 45: 6s8-76.
- Hirata H, Tsujii M, Yoshida T, Imanaka-Yoshida K, Morita A, Okuyama N, Nagakura T, Sugimoto T, Fujisawa K, Uchida A. (2005). MMP-2 expression is associated with rapidly proliferative arteriosclerosis in the flexor tenosynovium and pain severity in carpal tunnel syndrome. *J Pathol.* 205: 443-450.
- Huisstede BMA, Hoogvliet P, Franke TPC, Randsdorp MS, Koes BW (2017). Carpal Tunnel Syndrome: Effectiveness of Physical Therapy and Electrophysical Modalities. An Updated Systematic Review of Randomized Controlled Trials. *Arch. Phys. Med. Rehabil.* 31094-31098.
- Kang YM, Lee HM, Moon SH, Kang H, Choi YR (2017). Relaxin Modulates the Expression of MMPs and TIMPs in Fibroblasts of Patients with Carpal Tunnel Syndrome. *Yonsei Med J.* 58: 415-422.
- Karaarslan N, Gurbuz MS, Caliskan T, Ayan E, Aker FV, Berkman MZ (2016). The Effect of Matrix Metalloproteinase-3 on the Prognosis and Biological Behaviour of Meningiomas. *Turk. Neurosurg.* 26: 678-683.
- Kececi H, Degirmenci Y (2006). Hormone replacement therapy in hypothyroidism and nerve conduction study. *Neurophysiol. Clin.* 36: 79-83.
- Kim YH, Jung JC, Jung SY, Kim YI, Lee KW, Park YJ (2015). Cyclosporine A Downregulates MMP-3 and MMP-13 Expression in Cultured Pterygium Fibroblasts. *Cornea.* 34: 1137-1143.
- Kokkalis ST, Mavrogenis AF, Vottis C, Papatheodorou L, Papagelopoulos PJ, Soucacos PN, Sotereanos DG (2016). Median nerve biodegradable wrapping: Clinical outcome of 10 patients. *Acta Orthop Belg.* 82: 351-357.
- Kumar N, Gadpayle AK, Roshan S (2012). Thyrotoxic myopathy. *J Indian Acad. Clin. Med.* 13: 255-256.
- Lee JJ, Ruta DJ, Lien JR, Brunfeldt A, Lawton JN, Ozer K (2014). Arcus venosus dorsalis pedis: morphological considerations for use

- in superficial palmar arch reconstruction. *J Hand Surg.Am.* 39: 2243-2245.
- Li Pi Shan R, Nicolle M, Chan M, Ashworth N, White C, Winston P, Winston P, Dukelow S (2016). Electrodiagnostic Testing and Treatment for Carpal Tunnel Syndrome in Canada. *Can J Neurol. Sci.* 43: 178-182.
- Lim YH, Chee DY, Girdler S, Lee HC (2017). Median nerve mobilization techniques in the treatment of carpal tunnel syndrome: A systematic review. *J. Hand Ther.* 30: 397-406.
- Liu B, Pang B, Wang Q, Yang S, Gao T, Ding Q, Liu H, Yang Y, Fan H, Zhang R, Xin T, Xu G, Pang Q (2017). EZH2 up regulation correlates with tumor invasiveness, proliferation, and angiogenesis in human pituitary adenomas. *Hum Pathol.* 66: 101-107.
- Lockwood CJ, Krikun G, Hausknecht VA, Papp C, Schatz F (1998). Matrix Metalloproteinase and Matrix Metalloproteinase Inhibitor Expression in Endometrial Stromal Cells during Progestin-Initiated Decidualization and Menstruation-Related Progestin Withdrawal. *Endocrinology.* 139: 4607-4613.
- Mackinnon SE, Novak CB (2011). Compression Neuropathies. In: Wolfe SW, Hotchkiss RN, Pederson WC, Kozin HS, editors. *Green's Operative Hand Surgery*, Philadelphia: Churchill Livingstone Elsevier. 985–994.
- Papatheodorou LK, Sotereanos DG (2015). Treatment recommendations for carpal tunnel syndrome and peripheral nerve repair. *Instr Course Lect.* 64: 273-280.
- Spinner RJ, Amadio PC (2003). Compressive neuropathies of the upper extremity. *Clin. Plast. Surg.* 30: 155–173.
- Ulrich D, Hrynyschyn K, Pallua N (2003). Matrixmetalloproteinases and tissue inhibitors of metalloproteinases in sera and tissue of patients with Dupuytren's disease. *Plast. Reconstr. Surg.* 112: 1279-1286.
- Ulrich D, Ulrich F, Piatkowski A, Pallua N (2009). Expression of matrixmetalloproteinases and their inhibitors in cords and nodules of patients with Dupuytren's disease. *Arch. Orthop. Trauma. Surg.* 129: 1453-1459.
- Werner RA, Albers JW, Franzblau A, Armstrong TJ (1994). The relationship between body mass index and the diagnosis of carpal tunnel syndrome. *Muscle and Nerve.* 17: 632-636.
- Wolny T (2017). TheUse of Neurodynamic Techniques in the Conservative Treatment of Carpal Tunnel Syndrome- a Critical Appraisal of the Literature. *Ortop. Traumatol. Rehabil.* 19: 427-440.
- Yilmaz I, Gokay NS, Bircan R, Saracoglu GV, Dervisoglu S, Gokce A (2013). How different methodologies of harvesting and analysing the samples affect the test results in determining joint mediators. *Arthritis.* 2013:631959.