

Original Research Article

Computed Tomographic Evaluation of Anatomical Variations of Paranasal Sinuses Region in Rhinosinusitis

Ohood A. Mohammed¹, Mohamed Yousef^{1,2}, Ahmed Abukonna¹, Salem Saeed Alghamdi³, Ikhlas Abdelaziz^{1,3*} and Nasraldeen Alnaeem M. Alkhidir⁴

Abstract

¹College Of Medical Radiological Sciences, Sudan University Of Science And Technology, Khartoum, Sudan

²Batterjee Medical College, Jeddah, KSA

³Applied Radiologic Technology Department, University of Jeddah Jeddah, Saudi Arabia

⁴Radiologic Technology Department, college of applied medical sciences, Qassim University, Saudi Arabia

*Corresponding Author's E-mail: ikhlasabdelaziz888@gmail.com

Anatomical variations are very important to be identified when planning a paranasal sinus (PNS) surgery. Conventional radiology does not permit a detailed study of anatomical variations of the nose and paranasal sinuses; there is lack of studies in Saudi Arabia resident in this entity to Study Anatomical Variations of Para nasal sinus (PNS) using Multislice Computed Tomography (MSCT) in Rhinosinusitis. A cross-sectional hospital-based study of 392 patients, 272 males, 120 females, referred for CT scan of PNS was conducted from 2017 to 2019, this study was done in Riyadh Hospitals, Saudi Arabia, mostly from Consultant Radiologists Diagnostic Center selected all complaining from rhinosinusitis using Toshiba Alexion 16 slice. The images were evaluated for the presence of any anatomical variants in paranasal sinuses. The results of this study revealed that the absolute frequency of anatomical variations among 392 is 91.3% deviated nasal septum, concha bullosa seen in 50.77%, agger nasi cell found in 51.02%, Basal lamella pneumatization found in 5.36%. The superior turbinates were pneumatized in 20.15%. The crista galli was pneumatized in 19.39%. frontal sinus was hyper pneumatized in 8.67% and non pneumatized in 4.85%, The middle turbinate found to be paradoxical in shape in 10.71%. lamina papyracea dehiscence in 1.79%, inferior turbinate was pneumatized in 1.28%. The frontal air-cell was not present in our studied group. The supraorbital air-cell was present in 16.07%. The Onodi air-cell found to be present in 12.24%. The Haller air-cell found to be present in 30.10%. The sphenoid sinus is laterally pneumatized in 7.65%. The depth of cribriform plate (Keros classification) was in 0.51%. The infraorbital air-cell was present in 10.20%, nasal septum spur was presented in 29.34%, prominent ethmoidal bulla was presented in 29.85%, uncinat process was pneumatized in 12.76%, sphenoid sinus extension into posterior nasal septum is presented in 36.22%, posterior floor of sella turcica was pneumatized in 30.87%, the pterygoid process was pneumatized in 7.91%, anterior clinoid process was pneumatized in 10.97%, hard palate was pneumatized in 9.18% and lastly sphenoid septum change the direction in 8.16%. Anatomical variations of paranasal sinuses are best depicted on MDCT (multi detector computed tomography) scan of PNS. The deviated nasal septum is the commonest anatomical variation (93.11%) followed by agger nasi cell (51.02%).

Keywords: Anatomic variations, Deviated nasal septum, Para-nasal sinuses, Computed tomographic evaluation, Rhinosinusitis

INTRODUCTION

Sinonasal diseases, especially rhino-sinusitis, are commonly encountered health problems in otorhino-

laryngology practice. Variations in sinonasal anatomy such as the deviated nasal septum, enlarged turbinates,

etc are common in the population (Gebrim, 2008). Chronic rhinosinusitis is a common condition in which the paranasal sinuses (PNS) become inflamed and swollen for at least eight weeks despite treatment attempts (Fadda et al., 2012). It is also known that chronic rhinosinusitis interferes with drainage and causes mucus to build up. It is one of the most common illnesses of our times, and it is increasing in epidemic proportions throughout the world (Shpilberg et al., 2015). Chronic or recurrent sinusitis has been known to negatively impact health-related quality of life (Alkire and Bhattacharyya, 2010).

Its pathophysiology seems to be multi-factorial. The approach to patients with chronic rhino-sinusitis has changed after Messerklinger published the first comprehensive account of the technique of nasal endoscopy and its application to the diagnosis and treatment of sinonasal diseases (Messerklinger, 1978).

The prevalence of these variations differs in various ethnic populations (Badia et al., 2005). Role of sinonasal anatomical variations in the causation of chronic rhinosinusitis is still debated though it cannot be ruled out altogether (Gebrim, 2008; Jones, 2002). Although sinusitis is a clinically diagnosed condition, imaging studies are used to assess the disease and demonstrate the sinonasal anatomy (Kaygusuz et al., 2014).

Computed tomography (CT) scan plays a fundamental role in the diagnosis of anatomical variations as well as of sinonasal diseases for better guidance in the decision making about clinical, therapeutic and surgical approaches. Spiral CT provides axial and coronal images that facilitate a good appreciation of the size and relationship of the paranasal sinuses. It is currently the gold standard to study the imaging modality of choice for evaluating paranasal sinuses and adjacent structures (Kaygusuz et al., 2014; Mamatha et al., 2010). MSCT with its capability of displaying bone and soft tissues is the current diagnostic modality of choice for evaluating the ostiomeatal complex. MSCT is used both as a diagnostic tool to identify anatomical anomalies and mucosal pathology and as a preoperative map to guide the surgeon through the challengingly convoluted and variable anatomy of the area (Shpilberg et al., 2015; Alkire and Bhattacharyya, 2010).

MATERIAL AND METHODS

Subjects

This study has been done in Riyadh Hospitals, Saudi Arabia, mostly from Consultant Radiologists Diagnostic Center selected all complaining from rhinosinusitis and have one or more of the anatomic variant of paranasal sinuses. This retrospective study included 392 patients,

272 males, 120 females; their ages classified into five age groups, (18-28 year, 28-38 years, 38-48 years, 48-58 years, 58-68 years). Referred for paranasal CT scan, CT cut thickness is 1 millimeter or less was done. We excluded candidates those who have, trauma or surgery that disturbed their normal anatomy.

Equipment used

CT machine (Toshiba Alexion 16 slice)

Protocol done

Axial PNS, Coronal PNS, Sagittal PNS

METHOD

Data were collected and analyzed using the data collection sheet and SPSS in a period of 12 months. We reviewed the records of cross-Sectional study for 450 adult patients who underwent computed tomography of PNS for different indications. We applied the inclusion criteria (patients whose age 18 years and above, and patient who have rhinosinusitis) and exclusion criteria (trauma or surgery that disturbed their normal anatomy) for them. Patients (gender, age, habit, occupation, signs and symptoms, family history, living areas, disease duration) was evaluated and discussed. Our findings were compared with the literature.

RESULTS AND DISCUSSION

Sino nasal anatomy is very complex clinically and radiologically. What makes it more complex is the wide variety of anatomical variations that may influence the path physiology and the surgical procedures in this area (Fadda et al., 2012). Therefore, it needs to be well understood by the surgeon. Endoscopic sinus surgery is a fine procedure, in which the surgeon should be meticulous and well oriented about each part of this complex anatomy. The English literature is rich in the description of anatomical variation of paranasal sinuses, but there is a lack of such studies among Saudi Arabia resident. Studying and reporting these variations should be helpful for otorhinolaryngologist to consider those variations while dealing with their patients in our region and for planning the surgical interventions on them. In the human being, 4 pairs of paranasal sinus are there. Embryo logically developing in this sequence, ethmoid, maxillary, sphenoid and frontal. These sinuses have the different extent of development and pneumatization, and

Table 1. Analysis of chronic sinusitis according to the age (cross tabulation)
(Using chi-square test, P-value = 0.026)

Age	Distribution of sinusitis presence		Total
	acute	chronic	
18 - 28 y	24	58	82
28 - 38 y	64	90	154
38 - 48 y	59	42	101
48 - 58 y	18	21	39
58 - 68 y	9	7	16
Total	174	218	392

Table 2. Analysis of chronic sinusitis according to the gender (cross tabulation)
(Using chi-square test, P-value = 0.026)

Gender	Distribution of sinusitis presence		Total
	acute	chronic	
Male	137	135	272
Female	37	83	120
Total	174	218	392

Table 3. Analysis of chronic sinusitis according to the habit of smoking (cross tabulation)
(Using chi-square test, P-value = 0.006)

Habits	Distribution of sinusitis presence		Total
	acute	chronic	
Smoker	93	76	169
Non-smoker	81	142	223
Total	174	218	392

Table 4. Analysis of chronic sinusitis according to the occupation (cross tabulation)
(Using chi-square test, P-value = 0.000)

Occupation	Distribution of sinusitis presence		Total
	acute	chronic	
Accountant	34	45	79
Laborer	44	50	94
Medical profession	10	19	29
No job	19	23	42
Commercial career	25	24	49
Educational career	23	38	61
Legal career	2	3	5
Engineer	5	11	16
Administrator	12	5	17
Total	174	218	392

Table 5. Analysis of chronic sinusitis according to the signs and symptoms (cross tabulation)
(Using chi-square test, P-value = 0.000)

Signs and symptoms	Distribution of sinusitis presence		Total
	acute	chronic	
Dizziness	1	1	2
Nasal obstruction	5	8	13
Headache	109	167	276
Nasal discharge	54	36	90
Snoring	3	4	7
Reduced sense of smell	2	2	4
Total	174	218	392

Table 6. Analysis of chronic sinusitis according to the family history (cross tabulation)
(Using chi-square test, P-value = 0.055)

Family history	Distribution of sinusitis presence		Total
	acute	chronic	
Yes	76	101	177
No	98	117	215
Total	174	218	392

Table 7. Analysis of chronic sinusitis according to the living area (crosstabulation)
(Using chi-square test, P-value = 0.000)

Living area	Distribution of sinusitis presence		Total
	acute	chronic	
Apartment	126	164	290
Villa	45	51	96
Palace	3	3	6
Total	174	218	392

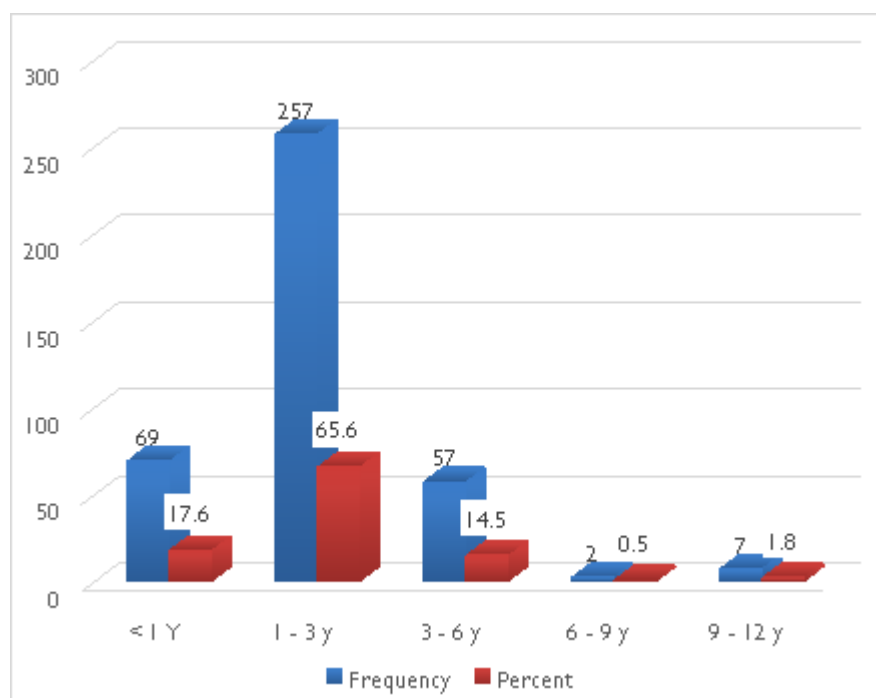


Figure 1. Distribution of samples according to disease duration

Table 8. Distribution of samples according to concha bullosa presence

Presence	Frequency	Percent	
yes	199	50.8	
No	193	49.2	
Side	RT	58	29.1
LT	44	22.1	
Bilateral	97	48.7	
Site	Middle	198	99.5
Inferior	1	.5	

Table 9. Distribution of samples according to hypertrophied nasal turbinate

Presence	Frequency	Percent	
yes	337	86.0	
No	55	14.0	
Side	RT	56	16.6
LT	61	18.1	
Bilateral	220	65.3	
Site	Superior	1	0.3
Middle	19	5.6	
inferior	317	94.1	

Table 10. Distribution of samples according to mucosal thickening

Presence	Frequency	Percent	
yes	245	62.5	
No	147	37.5	
Side	RT	35	14.3
LT	33	13.5	
Bilateral	177	72.2	

Table 11. Distribution of samples according to OMU obstruction

Presence	Frequency	Percent	
yes	89	22.7	
No	303	77.3	
Side	RT	19	21.3
LT	13	14.6	
Bilateral	57	64	

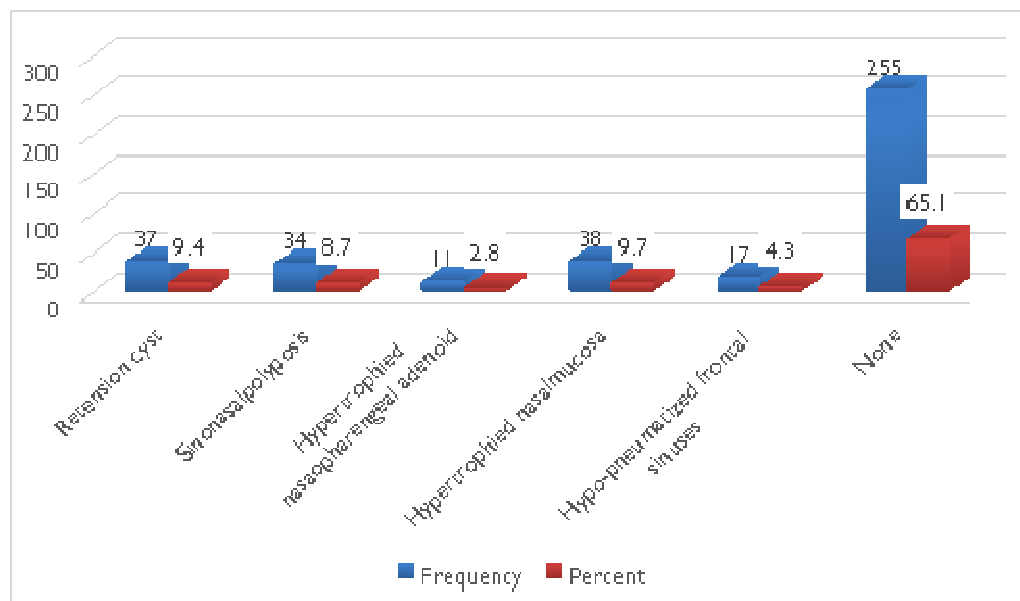


Figure 2. Distribution of samples according to the presence of other abnormalities

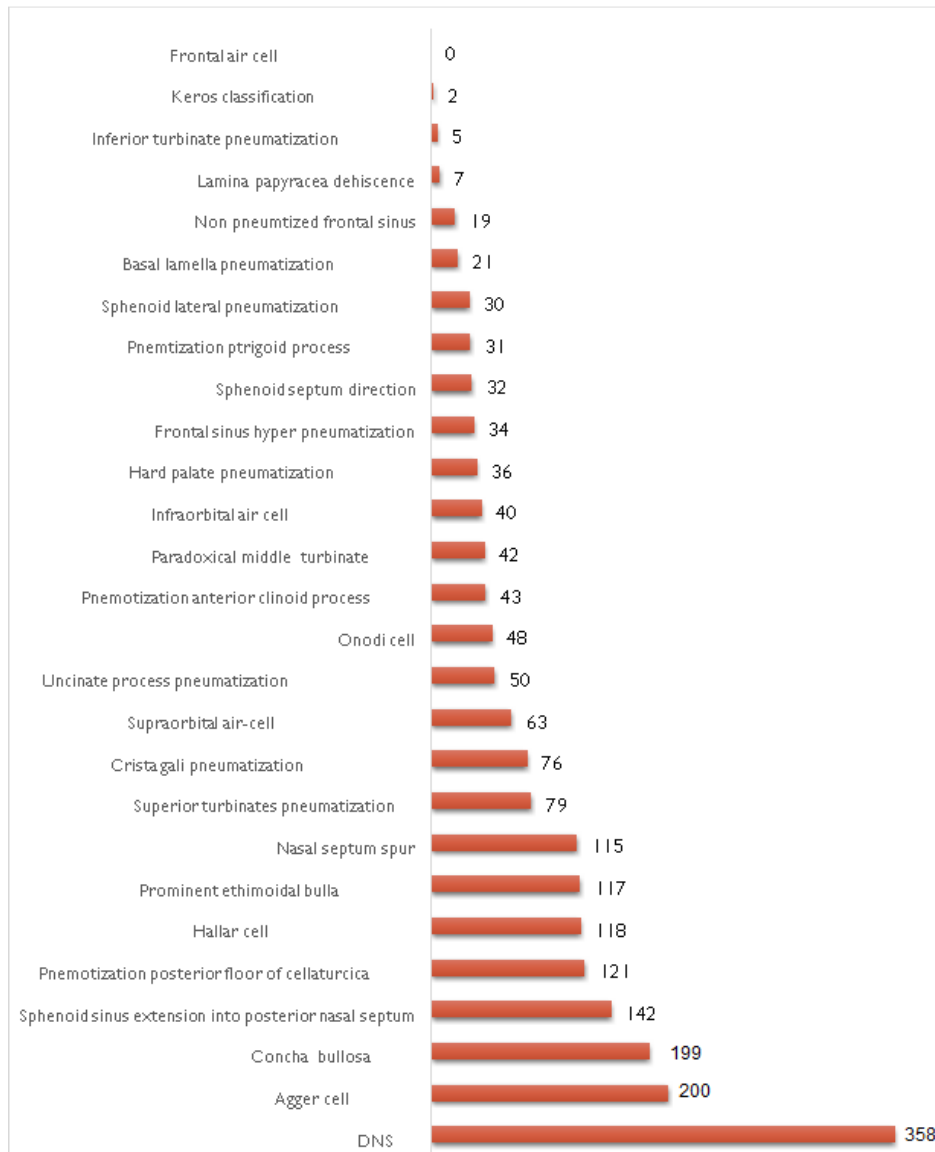


Figure 3. Distribution of the anatomical variation

variable relations with the surrounding structures, especially orbit and skull base. Also, the lateral nasal wall composed of three turbinate's, uncinat process and perpendicular plate of the palatine bone. Each of these structures has variant relations with sinuses, orbit and skull base (Roman et al., 2016; Adeel et al., 2013). The imaging investigation, CT as a gold standard, for the anatomical variation of the paranasal sinuses is very important these variations and in correlating them with the inflammatory changes of the paranasal sinuses. Also, it is very important for planning any surgical intervention. Inadvertent violation of the cribriform plate may cause CSF leak, direct penetration trauma to the dura, serious

intracranial and intra cerebral complications (Lebowitz et al., 2001; Başak et al., 2000). This study was conducted in Riyadh hospitals, Saudi Arabia, mostly from Consultant Radiologists Diagnose Center on 392 patients, 272 males, 120 females; the incidence of PNS diseases was more in males (69.4%), females (30.6%). Their ages ranged from 18 to 68 years, the majority of cases were found in age group from 28 to less than 38 years 154 Patients (39.3%). The most common indication was headache 276 Patient (70.4%). In the regional and domestic literature, two studies published tackling these variations one of them in the eastern province of Saudi Arabia evaluated 121 candidates (all of them are Saudis

Table 12. Prevalence of the anatomic variations of this study with comparison with some literature reports

Authors	Al-Qudah [2010]	Mamatha et al. [2010]	Fadda et al. [2012]	Adeel et al. [2013]	Al-Abri et al. [2014]	Roman et al. [2015]	Alrumaih et al [2016]	Ibrahim et al [2018]	current study[2019]
Country	Jordan	India	Italy	Pakistan	Oman	Romania	Saudi Arabia	Saudi Arabia	Saudi Arabia
Number of candidates	110	40	200	77	360	130	121	293	392
DNS	43	65	82	26	80	-	-	30.7	91.3
concha bullosa	62	15	2.8	18.2	49	35.3	55.4	24.2	50.77
crista galipneumatization	28	-	13.6	-	0.3	-	89.2	8.7	19.39
Paradoxical middle turbinate	18	-	6.4	14.3	13	8	12.4	9.5	10.71
Uncinate process pneumatization	-	40	-	-	-	46	-	73.7	12.76
Onodi cell	-	-	8.5	6	7.5	8	35	31.4	12.24
Haller cell	20	17.5	22.8	9.1	24	25	39.7	25.9	30.1
Sphenoid septum direction	-	-	-	-	0.8	-	-	29.7	8.16
Agger cell	84	50	34					97.5	51.02

population) and concluded that there is the difference of the prevalence of some variant among Saudi population compared with other study group (Alrumaih et al., 2016). The second one was done in southern Saudi Arabia evaluated 293 candidates (also they are all Saudi population) and concluded many differences as appear in the table (12) (Ibrahim et al., 2018).

The current study evaluated 392 candidates including all resident (Saudis and non-Saudis) and concluded too many findings Figure (3). Another domestic study conducted in Oman and concluded that deviation nasal septum (DNS) and conchabullosa (CB) are the most common in the Omani population Al-Abri et al., 2014). The most common anatomical variant in this study is DNS which is found in 358 (91.3%) cases similar to this study those who find that DNS is the most common are percentage ranging between 26-82% (Adeel et al., 2013, Ibrahim et al., 2018, Al-Abri et al., 2014; Fadda et al., 2012; Mamatha et al., 2010) table (12). Aggernasi is the second most common anatomical variation among Saudi resident it present in 200Pt (51.02)% it consider not too high percentage if as we compare with the reviewed literature (Ibrahim et al., 2018; Al-Qudah, 2010; Mamatha et al., 2010; Fadda et al., 2012) with the following percentage (97.5, 84, 50, 34)% table (12). CB is referred to as pneumatization of the middle turbinate, it was found in 199 (50.77%) of patients in this study. In the other studies reported prevalence of CB varies widely from 2.8-55.4% (Fadda et al., 2012; Mamatha et al., 2010; Roman et al., 2016; Adeel et al., 2013; 2006 Al-Abri et al., 2014;

Ibrahim et al., 2018; Al-Qudah, 2010; Alrumaih et al., 2016). table (12), In this study frontal air cell was not identified in any case unlike other studies mentioned in three studies (Fadda et al., 2012; Ibrahim et al., 2018; Alrumaih et al., 2016) table (12). In this study we mention many anatomic variants (Sphenoid sinus extension into posterior nasal septum, pneumatization posterior floor of sellaturcica, Prominent ethmoidal bulla, Nasal septum spur, hard palate pneumatization, pneumatization pterygoid process, Non pneumatized frontal sinus, Inferior turbinate pneumatization) by these frequencies (36.22, 30.87, 29.85, 29.34, 9.18, 7.91, 4.85, 1.28) figure (3) and all above variants are not mentioned in the literature. Anterior ethmoid artery (Al-Abri et al., 2014). Posterior ethmoid artery (Ibrahim et al., 2018) Table (12), Carotid artery dehiscence (Badia et al., 2005; Ibrahim et al., 2018; Alrumaih et al., 2016). Optic nerve dehiscence (Badia et al., 2005; Ibrahim et al., 2018; Alrumaih et al., 2016), all these anatomic variants are mentioned in the literature because they inject contrast media (CM) and in this study we did not use CM.

Lamina papyracea dehiscence (Dua et al., 2005), anterior clinoid process pneumatization (Nouraei et al., 2009), infraorbital air cell (Nouraei et al., 2009), all these variants mentioned in only one study of literature beside current study by these frequencies (4, 18, 12)% in the reviewed studies and these frequencies (1.79, 10.97, 10.20) (figure 3) in current study, and we notice our study frequencies is less for all of the three mentioned anatomic variants. Basal lamella pneumatiza-

tion is mentioned only in two previous studies (Perez Pinas et al., 2000; Ibrahim et-al., 2018) by these frequencies (15.7, 3.1) % while in this current study presented by 5.36%. Keros classification in this current study was considered to present by too low percentage 0.51% if we compared by other literature (Badia et al., 2005; Al-Abri et-al., 2014; Ibrahim et-al., 2018; Nouraei et al., 2009) by these percentage (27, 29, 36, 45.4, and 92) %.

CONCLUSION

The anatomical variation of the paranasal sinuses is very important to be identified preoperatively. These variations found to be different among regions and countries. In our study, we found all Patients with rhinosinusitis have one or more than one anatomic variant mentioned, deviated nasal septum is the commonest anatomical variation (93.11%), followed by agger nasi cell (51.02%).

REFERENCES

- Adeel M, Rajput MS, Akhter S, Ikram M, Arain A (2013). Anatomical variations of nose and para nasal sinuses; CT scan review. *J. Pakistan Med. Assoc.* 63(3): 317.
- Al Abri R, Bhargava D, Al-Bassam W, Al Badaai Y, Sawhney S (2014). Clinically significant anatomical variants of the paranasal sinuses. *Oman Med J* 29(2): 110-113.
- Alkire BC and Bhattacharyya (2010). An assessment of sinonasal anatomic variants potentially associated with recurrent acute rhinosinusitis. *Laryngoscope*, 120: 631–34
- Al-Qudah MA (2010). Anatomical variations in sinonasal region: A computer tomography (CT) study. *J Med J* 44(3): 290-297.
- Alrumaih RA, Mona M Ashoor, Ahmed A Ob (2016). Radiological sino nasal anatomy. Exploring the Saudi population. *Saudi Med J* 37: 521-526.
- Badia L, Lund VJ, Wei W, Ho WK (2005). Ethnic variation in sinonasal anatomy on CT- scanning. *Rhinology*. 43:210-4.
- Başak S, Akdilli A, Karaman CZ, Kunt T (2000). Assessment of some important anatomical variations and dangerous areas of the paranasal sinuses by computed tomography in children. *Int J Pediatr Otorhinolaryngol* 55(2): 81-89.
- Caughy RJ, Jameson MJ, Gross CW, Han JK (2005). Anatomic risk factors for sinus disease: fact or fiction? *American journal of rhinology* 19(4): 334-339.
- Dua K, Chopra H, Khurana AS, Munjal M (2005). CT scan variations in chronic sinusitis. *Indian Journal of Radiology and Imaging* 15(3): 315.
- Fadda GL, Rosso S, Aversa S (2012). Multi parametric statistical correlations between paranasal sinus anatomic variations and chronic rhinosinusitis. *Acta Otorhinolaryngol Ital.*; 32(4):244–51
- Gebrim ES (2008). The relevance of sinonasal anatomical variations in the preoperative evaluation by computed tomography for endo nasal surgery. *Radiol Bras.*; 41:56
- Ibrahim S, Saud A, Jibril H (2018). Anatomical Variations of Paranasal Sinuses Gender and Age Impact. *Glob J Oto* 14(1): 555877. DOI: 10.19080/GJO.2018.14.555877
- Jones NS (2002). CT of the paranasal sinuses: a review of the correlation with clinical, surgical and histopathological findings. *Clin Otolaryngol Allied Sci.* 27:11-7.
- Kaygusuz A, Haksever M, Akduman D, Aslan S, Sayar Z (2014). Sinonasal Anatomical Variations: Their Relationship with Chronic Rhinosinusitis and Effect on the Severity of Disease—A Computerized Tomography Assisted Anatomical and Clinical Study. *Indian J Otolaryngol Head Neck Surg.* 6:260–6.
- Lebowitz RA, Terk A, Jacobs JB, Holliday RA (2001). Asymmetry of the ethmoid roof: analysis using coronal computed tomography. *Laryngoscope* 111(12): 2122-2124.
- Lerdlum S, Vachiranubhap B (2005). Prevalence of anatomic variation demonstrated on screening sinus computed tomography and clinical correlation. *Journal of the Medical Association of Thailand Chotmaihetthangphaet* 88: S110-S115.
- Mamatha H, N.M. Shamasundar, M.B. Bharathi, L.C. Prasanna (2010). Variations of ostiomeatal complex and its applied anatomy: a CT scan study. *Indian journal of science and technology.* 3 (8):904-907.
- Mazza D, Bontempi E, Guerrisi A, Del Monte S, Cipolla G, Perrone A (2007). Paranasal sinuses anatomic variants: 64-slice CT evaluation. *Minerva Stomatol*; 56: 311-318.
- Messerlinger W (1978). *Endoscopy of the nose.* Baltimore, MD: Urban & Schwarzenberg.
- Nouraei SA, Elisay AR, Dimarco A, Abdi R, Majidi H (2009). Variations in paranasal sinus anatomy: implications for the pathophysiology of chronic rhinosinusitis and safety of endoscopic sinus surgery. *J Otolaryngol Head Neck Surg* 38(1): 32-37.
- Perez Pinas I, Sabate J, Carmona A, Catalina-Herrera CJ, Jimenez Castellanos J (2000). Anatomical variations in the human paranasal sinus region studied by CT. *The Journal of Anatomy* 197(2): 221-227.
- Roman RA, Hedeşiu M, Gersak M, Fidan F, Băciuţ G, Băciuţ M (2016). Assessing the prevalence of paranasal sinuses anatomical variants in patients with sinusitis using Cone.
- Shpilberg KA, Daniel SC, Doshi AH (2015). CT of anatomic variants of the paranasal sinuses and nasal cavity: Poor correlation with radiologically significant rhinosinusitis but importance in surgical planning. *Am J Roentgenol.*; 204(6): 1255–60
- Swaroop DM (2010). Clinical Study of Tumors of Nose and Paranasal Sinuses.