

Case Report

Outcome of switching antiangiogenic therapies in combination with FOLFRI as a treatment beyond second line for mutant K- RAS metastatic colorectal cancer

Rasha Aboelhassan

Abstract

Consultant of clinical oncology-
Nasser Institute Cancer Center-
EGYPT

E-mail: elsayedonco@hotmail.com
Orcid.org/0000-0003-4755-6105

Anti-angiogenesis targeted therapy in combination with chemotherapy is one of the limited options for systemic therapy beyond second line for patient with Ras mutant metastatic colorectal cancer. Aflibercept is an antiangiogenic therapy which improved survival for metastatic colorectal cancer with FOLFRI as a second line after failure of oxaliplatin containing regimen and can be used after failure of use of FOLFOX, or after failure of chemotherapy combination with bevacizumab, other options of antiangiogenic therapies include regorafenib or bevacizumab beyond disease progression. In this case report, the patient is a 53 years old male who had a multiple line of therapies for metastatic colorectal cancer (mCRC), including bevacizumab in combination with FOLFRI. He had complete remission confirmed by PET-CT after 6th cycle of aflibercept in combination with FOLFRI and reached progression free survival of eleven months. Aflibercept in combination with FOLFRI can give adequate Progression Free Survival (PFS) as a treatment beyond second line for good responder patients. This finding needs further research work and investigations.

Keywords: Aflibercept, Antiangiogenic therapy, mCRC, treatment beyond second line

INTRODUCTION

Aflibercept, an intravenously administered anti vascular endothelial growth factor (anti-VEGF) and antiplacental growth factor (PIGF) agent, has been approved on 2012 by the U.S. Food and Drug Administration in combination with 5-fluorouracil, leucovorin, and irinotecan (FOLFIRI) for the treatment of patients with metastatic colorectal cancer who have previously received an oxaliplatin-containing chemotherapy regimen. Aflibercept is a fully humanized recombinant fusion protein composed of portions of the extracellular domains of VEGF receptor

(VEGFR)-1 and VEGFR-2 fused to the Fc portion of human immunoglobulin G1 (Holash et al., 2002). In phase III VELOUR trial, aflibercept plus FOLFIRI for second line therapy for metastatic colorectal cancer resulted in statistically significantly prolonged both PFS (PFS; median PFS for the aflibercept plus FOLFIRI arm was 6.90 vs. 4.67 months for the placeboplus-FOLFIRI arm) and Overall Survival (OS) (Median OS for the aflibercept-plus-FOLFIRI arm was 13.50 vs. 12.06 months for the placebo plus FOLFIRI arm),

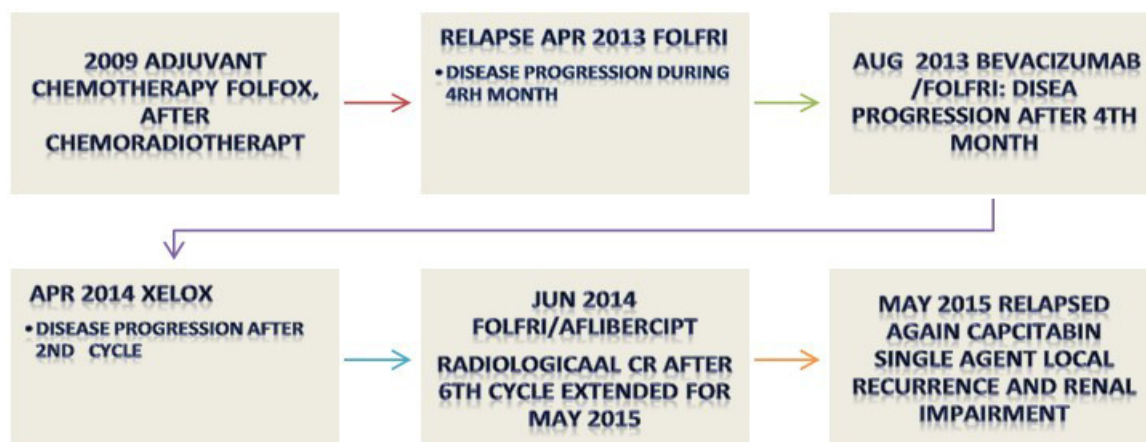


Figure 1. Combination regimens patient had as systemic therapy before and after aflibercept

but grade 3 or 4 adverse events were more common with the addition of aflibercept (Van Cutsem et al., 2012). But these results were not the same with FOLFOX combination (Pericay et al., 2012) in phase II AFFIRM trial.

Another option for mutant all RAS metastatic colorectal cancer in second line therapy is bevacizumab which is still showing improving survival even after disease progression in ML18147 (Bennouna et al., 2013) and showing good efficacy and safety profile (Guan et al., 2011).

Aflibercept and bevacizumab has different mechanism of action and different results of treatment as a second line but biologically; aflibercept was found to have higher affinity for VEGF-A, as well as its ability to bind VEGF-B and PIGF (Yu et al., 2011; Papadopoulos et al., 2012)

For treatment beyond second line therapy in mCRC, CORRECT trial Participants were randomized approximately 2:1 to receive regorafenib or placebo plus best supportive care. This trial showed a median OS of 6.4 months versus 5.0 months for regorafenib and placebo, respectively (HR = 0.77; 95% CI, 0.64-0.94; 1-sided P = .0052). A similar benefit in PFS was also seen for patients who received regorafenib relative to those who received placebo (HR = 0.49; 95% CI, 0.42-0.58; P < .0001), with a median PFS of 1.9 months and 1.7 months, respectively. Despite improvements in OS and PFS with regorafenib treatment, patients' health status and quality of life appeared to decline at a similar rate in both arms. (Grothey et al., 2013) Other than regorafenib, there is no targeted therapy option for treatment beyond second line for mCRC can give better DFS as a treatment beyond second line especially when the patient had a treatment failure on bevacizumab. In this case report the patient 53 years old with Kras mutant mCRC had a failure of treatment of three lines before having aflibercept in combination with FOLFRI as a line of

treatment beyond second line therapy. This line of therapy gave him 11 months of DFS and reached him to complete remission, so those switching from one antiangiogenic therapy to another can give a chance for treatment beyond second line for mutant type mCRC? Or did aflibercept give this response due to its broader antiangiogenic effect than bevacizumab?

Case Report

Male patient 53 years presented on APR- 2014 by relapsed RAS mutant colorectal cancer in lung associated with local recurrence.

He gave a history of surgery for stage III on 2009 followed by radiation therapy and adjuvant FOLFOX, he was on regular follow up till APR-2014 when he had dysuria and with urology examination, a pelvic mass was found obstructing left ureter, where a ureteric stent was fixed and a tumor biopsy was taken showing: adenocarcinoma of colonic origin.

Further evaluation for this patient showed the presence of lung metastases and performance status of 1 with no other history of chronic diseases and he has base line normal labs.

The patient had a first line of treatment for mCRC in the form of FOLFRI with treatment failure during the fourth cycle. That was followed by a combination of bevacizumab with FOLFRI regimen as a second line therapy for mCRC mutant type; unfortunately, he had treatment failure after 4th cycle again. That was followed by XELOX for 2 cycles showing further disease progression after second cycle. Figure 1.

On June 2014, there were limited options of therapy and after discussion of the condition of the patient we decided to take the challenge for switching type of antiangiogenic therapy: and give aflibercept in-

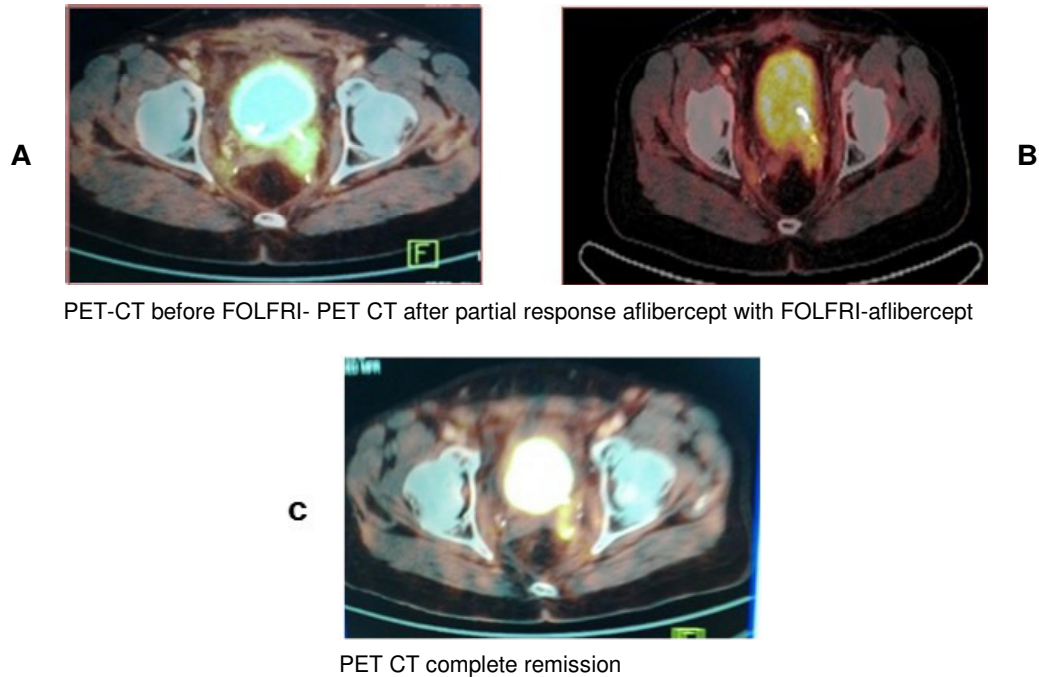


Figure 2. (A) base line PET- CT before aflibercept combination, (B) PET_CT first evaluation showing partial remission of left iliac lymph-node invading left ureter, (C) PET-CT showing complete disappearance of left iliac lymph-node leaving dilated left ureter

combination with FOLFRI which resulted in partial remission during the first three cycles and disappearance of lung metastases. Figures (1,2) and reached complete remission after 6th months of therapy on Jan 2015, and that was followed by local radiation therapy to previous site of local recurrence.

The patient had a good treatment tolerance with no significant toxicities, he had grade II hand and foot syndrome, diarrhea, neutropenia and no evidence of venous thromboembolism, GIT perforation or any adverse events were reported.

We found no scientific evidence to continue on aflibercept after complete remission for this patient, so had to put our patient on follow up for PET CT every three months.

On May 2015 patient presented by new lesion in the form of a mass invading urinary bladder and causing obstructive uropathy, cystoscopy and biopsy was done showing adenocarcinoma of colonic origin invading urinary bladder.

Supportive care was given for the patient as a treatment for pain and to ureteric stent was fixed. Upon relieve of urinary tract obstruction we discussed with our patient further treatment by other lines of therapy like regorafenib but unfortunately he could not afford more biological therapy.

He was put on maintenance therapy by capecitabine

and he passed away 6 months later

DISCUSSION

Options for treatment beyond second line therapy for RAS mutant mCRC are limited, especially when we discuss with our patients' treatment targets like quality of life, PFS and OS comparing them with cost of biological therapies.

The current available antiangiogenic therapy option for this group of patients is regorafenib, which can be used after failure of two lines of therapies and cytotoxic chemotherapy, but other antiangiogenic therapies were not approved for the use beyond second line till now (Grothey et al., 2013; NCCN guidelines version 1, 2017).

There is still no adequate evidence that different mechanisms of action for different antiangiogenic therapies can impact on treatment results, but there is preclinical evidence suggesting that differences between bevacizumab and ziv-aflibercept might be clinically relevant.

The more efficient and potent binding of ziv-aflibercept to VEGF-A, by up to 3 logs, when compared with bevacizumab, has been well documented in cell-free systems, and this enhanced ligand binding has been

associated with more potent biologic activity (Yu et al., 2011; Papadopoulos et al., 2012).

Our patient had treatment failure for multiple lines of treatment including antiangiogenic therapy bevacizumab but he had radiological complete remission with treatment by antiangiogenic therapy aflibercept with FOLFIRI, the one explanation for this condition is that aflibercept has a wider range for anti-angiogenesis which can overcome antiangiogenic treatment resistance that was occurred during bevacizumab treatment, and also the potent binding of aflibercept to VEGF-A.

Another explanation for response of our patient to switching from bevacizumab to aflibercept as a treatment beyond second line may be in a VELOUR study subset analysis (Chau et al., 2014): patients with fast relapse less than 6 months, were excluded, and patient were identified as good responders when having performance status of 1 and less number of metastatic sites like our patient who had a relapse after four years of follow up, performance status 1 and only two sites of metastases after adjuvant therapy. Those patients might have the chance of benefit from aflibercept not only as a second line of treatment, but also as a treatment beyond second line in case there is a tumor resistance to bevacizumab. In VELOUR study, median number of cycles were 7 and 21 weeks of treatment, in contrast our patient had 24 weeks for 6 cycles with disease remission at 24 weeks at 6th cycle and this response was maintained for 11 months which can give hope for further treatment options and response for mutant Ras mCRC and this line of treatment need further research.

As long as this patient was treated before FDA approval of immunotherapy in mCRC, this type of therapy was not an option of treatment.

CONCLUSION

Switching between antiangiogenic therapies as a treatment beyond second line therapy for patient with mCRC need further investigation and could have a new hope in presence of limited options for treatment in this group of patients

ACKNOWLEDGEMENT

We thank our patient and his wife who accepted to publish his case to give chance for other patients and oncologist to get benefit from his treatment details. We

thank Nasser Institute Cancer Center Oncology Committee and all workers for their help during follow up of this patient.

REFERENCES

- Bennouna J, Sastre J, Arnold D, Österlund P, Greil R., Van Cutsem E, von Moos R, Viéitez JM, Bouché O, Borg C, Steffens CC (2013). Continuation of bevacizumab after first progression in metastatic colorectal cancer (ML18147): a randomised phase 3 trial. *The lancet oncology*, 14(1), pp.29-37.
- Chau I, Joulain F, Iqbal SU, Bridgewater J (2014). A VELOUR post hoc subset analysis: prognostic groups and treatment outcomes in patients with metastatic colorectal cancer treated with aflibercept and FOLFIRI. *BMC cancer*, 14(1), p.605.
- Grothey A, Van Cutsem E, Sobrero A, Siena S, Falcone A, Ychou M, Humblet Y, Bouché O, Mineur L, Barone C, Adenis A. Regorafenib monotherapy for previously treated metastatic colorectal cancer (CORRECT): an international, multicentre, randomised, placebo-controlled, phase 3 trial. *The Lancet*. 2013 Feb 1;381(9863):303-12.
- Guan ZZ, Xu JM, Luo RC, Feng FY, Wang LW, Shen L, Yu SY, Ba Y, Liang J, Wang D, Qin SK (2011). Efficacy and safety of bevacizumab plus chemotherapy in Chinese patients with metastatic colorectal cancer: a randomized phase III ARTIST trial. *Chinese journal of cancer*, 30 (10), p.682.
- Holash J, Davis S, Papadopoulos N, Croll SD, Ho L, Russell M, Boland P, Leidich R, Hylton D, Burova E, Ioffe E (2002). VEGF-Trap: a VEGF blocker with potent antitumor effects. *Proceedings of the National Academy of Sciences*, 99(17), pp.11393-11398.
- National Comprehensive Cancer Network colon cancer version 1 2017 https://www.nccn.org/professionals/physician_gls/pdf/colon.pdf.
- Papadopoulos N, Martin J, Ruan Q, Rafique A, Rosconi MP, Shi E, Pyles EA, Yancopoulos GD, Stahl N, Wiegand SJ (2012). Binding and neutralization of vascular endothelial growth factor (VEGF) and related ligands by VEGF Trap, ranibizumab and bevacizumab. *Angiogenesis*, 15(2), pp.171-185.
- Pericay C, Folprecht G, Saunders M, Thomas A, Roh JK, Lopez R, Hoehler T, Kim JS, Zillocchi C, Boelle E, Zalberg J (2012, June). Phase 2 randomized, noncomparative, open-label study of aflibercept and modified FOLFOX6 in the first-line treatment of metastatic colorectal cancer (AFFIRM). In *Annals of Oncology* (Vol. 23, pp. 16-16). GREAT CLARENDON ST, OXFORD OX2 6DP, ENGLAND: Oxford univ press.
- Van Cutsem E, Tabernero J, Lakomy R, Prenen H, Prausová J, Macarulla T, Ruff P, van Hazel GA, Moiseyenko V, Ferry D, McKendrick J (2012). Addition of aflibercept to fluorouracil, leucovorin, and irinotecan improves survival in a phase III randomized trial in patients with metastatic colorectal cancer previously treated with an oxaliplatin-based regimen. *J. Clin. Oncol*. 30(28), pp.3499-3506.
- Yu L, Liang XH, Ferrara N (2011). Comparing protein VEGF inhibitors: in vitro biological studies. *Biochem Biophys Res Commun*; 408:276-81.