

*Original Research Article*

# The clinical research of $^{18}\text{F}$ -FDG PET/CT in peripheral lung cancer

MingMing YU Ph.D, \*Zhen Guang Wang MD., Yan Kong BS, Yue Hua Chen MS  
and Qian Yu MS

## Abstract

PET/CT Center, Affiliated Hospital of  
Qingdao University, No. 59, Haier Rd.,  
Qingdao 266100, China

\*Corresponding Author's E-mail:  
ymmcyh@126.com  
Tel: 18661803816

This retrospective study aimed to evaluate the  $^{18}\text{F}$ -fluorodeoxyglucose ( $^{18}\text{F}$ -FDG) positron emission tomography (PET)/ computed tomography (CT) imaging characteristics of peripheral lung cancer. 50 patients with peripheral lung cancer confirmed by biopsy and pathology were examined by  $^{18}\text{F}$ -FDG PET/CT. A retrospective study was performed to evaluate the difference of the maximum standardized uptake value (SUVmax) in selected regions of interest (ROI) between adenocarcinoma and squamous cell carcinoma, and the correlation between ROI's SUVmax and tumor sizes. Studies were interpreted by 2 experienced radiologists. Positive rate for malignant was about 92% and negative rate was about 8% when the SUVmax of 2.5 is used for the cutoff point. There were significant differences ( $p < 0.05$ ) between the SUVmax of adenocarcinoma and that of squamous cell carcinoma. The sizes of 50 cases of peripheral lung cancer were correlated with the SUVmax ( $r = 0.674$ ,  $p < 0.001$ ) in ROI.  $^{18}\text{F}$ -FDG PET/CT demonstrates an excellent performance in diagnosing lung cancer. The combination of anatomic and metabolic imaging provides valuable information for the clinic.

**Keywords:** Peripheral lung cancer, positron emission tomography/computed tomography (PET/CT),  $^{18}\text{F}$ -fluorodeoxyglucose ( $^{18}\text{F}$ -FDG)

## INTRODUCTION

Lung cancer is the leading cause of cancer related deaths for both men and women in developed countries (Bunyaviroch and Coleman, 2006). Positron emission tomography (PET) with integrated computed tomography (CT) imaging is the most advanced functional imaging techniques at present.  $^{18}\text{F}$ -fluorodeoxyglucose ( $^{18}\text{F}$ -FDG) can be used as an imaging agent based on the principle of elevated glucose metabolism in malignant tumors (Koolen et al., 2012).  $^{18}\text{F}$ -FDG PET/CT imaging has been widely used to diagnose many kinds of tumors. Most of lung cancer is FDG-avid except some low-grade malignant tumors such as part of well differentiated lung cancer and bronchioloalveolar cancer. Some benign diseases such as tuberculosis, granuloma, inflammation

and fungal infections can show different degree of  $^{18}\text{F}$ -FDG metabolism so that it is difficult to diagnose the lung cancer using  $^{18}\text{F}$ -FDG PET only because of the false positive and false negative results.  $^{18}\text{F}$ -FDG PET with integrated CT will be a better choice to diagnose the peripheral lung cancer.

## Patients and Methods

### Patients

50 patients (34 males, 16 females; age range: 35–76 years old; mean age: 64 years old) with the peripheral

lung cancer were enrolled in this study. All patients had a definite diagnosis based on biopsy result. Each patient received the whole body  $^{18}\text{F}$ -FDG scan described below.

### Imaging Acquisition

$^{18}\text{F}$ -FDG was produced by Shanghai atomic KeXing pharmaceutical Co., LTD. Radiochemical purity (>95%) of  $^{18}\text{F}$ -FDG was verified by analytical HPLC. All patients fasted for at least 6 hours before PET/CT examination. After ensuring a normal peripheral blood glucose level, patients received an intravenous injection of 0.2mCi/kg of  $^{18}\text{F}$ -FDG, and then rested for approximately 60 minutes before undergoing a PET/CT examination. Image acquisition was performed using an integrated PET/CT device (GE Discovery VCT). CT was performed from the head to the pelvic floor using a standardized protocol (120KV, 130mA with a slice thickness of 3.75mm). The acquisition time for PET was 3 minutes per bed position and 6-7 continuous positions were scanned. PET images datasets were reconstructed iteratively using an ordered subset expectation maximization algorithm and corrected with measured attenuation correction. The SUVmax of the selected ROI in lesions was calculated. CT, PET, and PET/CT infusion images were obtained through a post processing procedure.

### Data Analysis and Processing

ROI was drawn on the slice that showed clearly radioactivity aggregation. A SUVmax of 2.5 is defined as a threshold for the distinction between positive and negative. CT images were mainly employed to examine the morphology of pulmonary lesions.

The images were interpreted by two experienced radiologists who had obtained a position higher than the rank of attending physicians. Diagnosis was determined only when a consensus was achieved. If no consensus was achieved, it would be subject to further review by the whole department. The correlation of the SUVmax between adenocarcinoma and squamous cell carcinoma, the correlation between ROI's SUVmax and tumor sizes were quantitatively compared.

### Statistical Analysis

SPSS software (version 13.0) was used for statistics. The correlations of the SUVmax between adenocarcinoma and squamous carcinoma were performed using t-test. The correlations between tumor sizes and the SUVmax were performed using pearson correlation analysis.

## RESULTS

### Patients

There were 50 patients with peripheral lung cancer, 38 cases of adenocarcinoma (including 2 cases of mucinous carcinoma), 10 cases of squamous cell carcinoma and 2 cases of small cell non-differentiated adenocarcinoma.

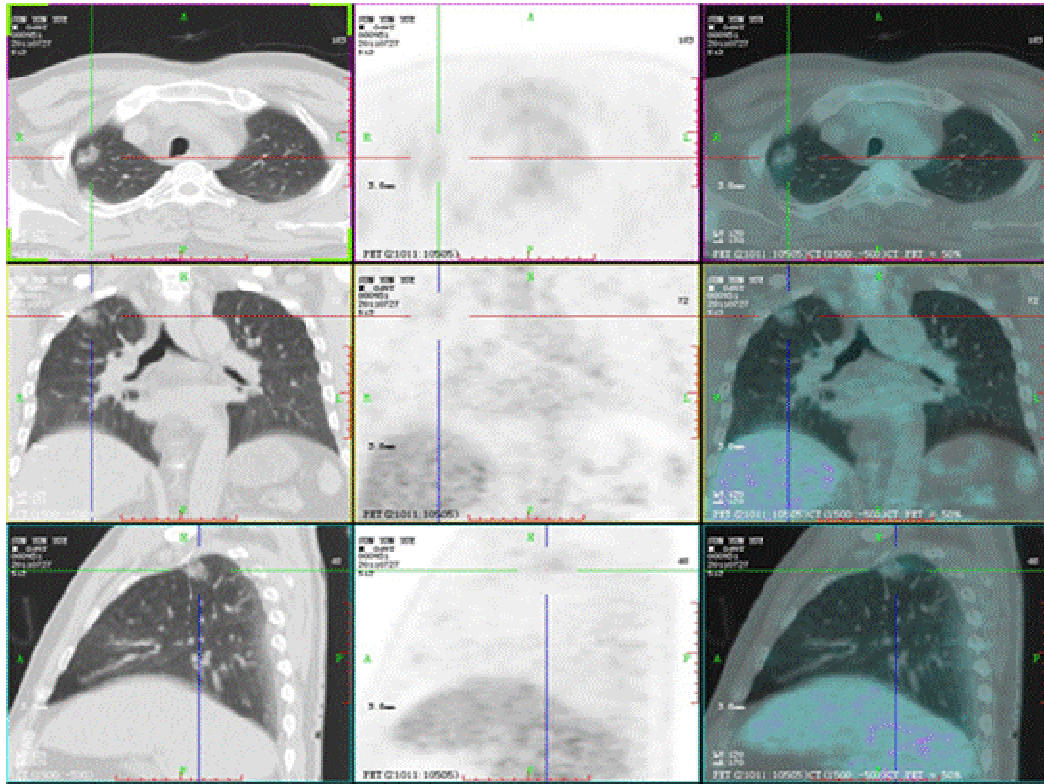
### Image Analysis

PET image of 50 cases of peripheral lung cancer were analysed. There were 46 cases with high  $^{18}\text{F}$ -FDG uptake ( $\text{SUVmax} \geq 2.5$ ) and 4 cases with slightly  $^{18}\text{F}$ -FDG uptake ( $\text{SUVmax} < 2.5$ ) in this examination. The positive rate was 92% and the negative rate was 8%. There were 2 highly differentiated adenocarcinoma, 1 highly differentiated adenocarcinoma partly with alveolar cell carcinoma and 1 alveolar cell carcinoma in the 4 cases with slightly  $^{18}\text{F}$ -FDG uptake. The lowest SUVmax in the 4 cases is 1.11 for the initial scan (Figure 1) and 1.52 for the delayed scan.

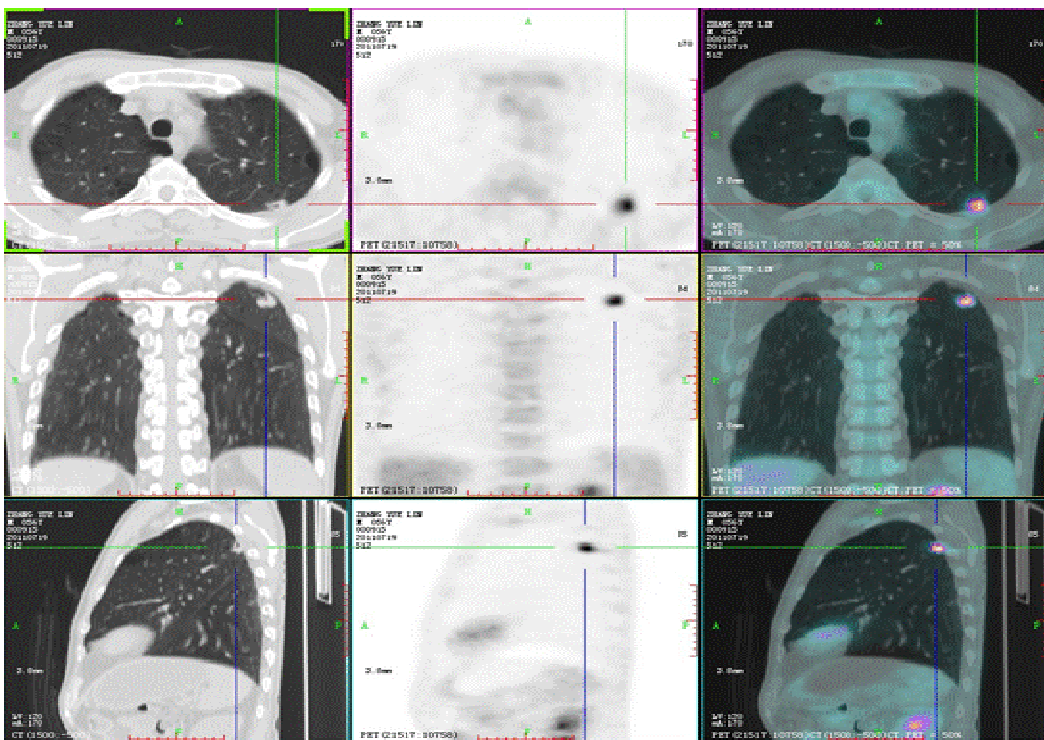
There were totally 38 cases of adenocarcinoma, 18 of them with a diameter lower than 3.0cm and 20 of them with a diameter great than or equal to 3.0cm. The range of the SUVmax of the 38 cases of adenocarcinoma is from 1.12 to 18.20 and the average SUV is 7.82. The SUVmax is from 6.52 to 19.23 in the 10 cases of squamous cell carcinoma with the diameter great than 3.0 cm and the average SUV is 13.11. The SUVmax of the 2 cases of small cell lung cancer with diameter lower than 3.0 cm is 4.71 and 7.93 separately and the average SUV is 6.32 (Figure 2). CT imaging shows the positive rate of lobulation sign, pleural indentation, speculated sign, vessel convergence and vacuole sign were 68%, 92%, 80%, 76%, 24% separately in the 50 cases of peripheral lung cancer.

### Statistical Results

The results from a statistical analysis showed that the SUVmax of 10 cases of squamous cell carcinoma was obviously higher than that of 38 cases of adenocarcinoma ( $P < 0.05$ , the sizes of 50 cases of peripheral lung cancer were significantly correlated with the ROI's SUVmax ( $r=0.674$ ,  $p < 0.001$ ), the sizes of 38 cases of adenocarcinoma were significantly correlated with the ROI's SUVmax ( $r=0.610$ ,  $p < 0.001$ ), the sizes of 10 cases of squamous cell carcinoma were significantly correlated with the ROI's SUVmax ( $r=0.745$ ,  $p < 0.001$ ).



**Figure 1.** Ground-glass opacity in the upper lobe of right lung. The size in lung window was about 2.86 x 1.90 cm and the density was uneven. The radioactive uptake was mild increased and the SUVmax was 1.11. Pathological results showed adenocarcinoma.



**Figure 2.** A nodule with lobulated shape in the upper lobe of left lung. The size in lung window was 1.58x1.16cm. The radioactive uptake of the nodule is high and the SUVmax 4.71. Pathological results showed small cell lung cancer.

## DISCUSSION

<sup>18</sup>F-FDG PET, in contrast with CT, is a tool that reflects cancer metabolism and cell biology. Recently, FDG-PET combined with CT has been introduced and is expected to give us precise anatomical data with metabolic information. Fusion PET/CT has been reported to be useful to stage lung cancer, colorectal carcinoma, breast cancer, lymphoma, head and neck cancer and to detect recurrence of lung, colorectal, thyroid, and breast cancer (Gamez et al., 2006; Chen et al., 2007; Even-Sapir et al., 2004; Yoshioka et al., 2003; Schöder et al., 2004; Freudenberg et al., 2004; Finkelstein et al., 2008; Veit-Haibach et al., 2007).

Among peripheral lung carcinomas, adenocarcinoma is the most common histological type. Adenocarcinoma usually occurred in female patients and the incidence rate was about 33% in all types of lung cancers. Most of the adenocarcinoma sited in the peripheral area of lung and about 50% of adenocarcinoma shows solitary pulmonary nodule in the CT image. Adenocarcinoma tends to metastasize by lymphatic route and hematogenous route in the early stage and the prognosis is poor. Adenocarcinoma with fibrous scar is common. Bronchioloalveolar carcinoma is one of the subtypes of adenocarcinoma and with diversity of imaging performance. Part of bronchioloalveolar carcinoma shows ground-glass nodule with slightly <sup>18</sup>F-FDG uptake (SUVmax < 2.5). There were 3 cases of ground-glass nodules in our research totally. 2 cases were well-differentiated adenocarcinoma and 1 case was alveolar cell carcinoma.

Squamous cell carcinoma was most common in lung cancer with an incidence rate of 40% to 50%. The incidence of squamous cell carcinomas arising from peripheral lung is increasing. In the past, most of squamous cell lung carcinomas were reported to develop in the central region of the lung (Asamura et al., 1996; Funai et al., 2003). Most of the patients with squamous cell carcinoma were old male with smoking history. The <sup>18</sup>F-FDG uptake of squamous cell carcinoma was relatively high than that of adenocarcinoma ( $p < 0.05$ ) in our research.

Small cell lung cancer characterized by high malignancy is more common in young men with smoking history. Small cell lung cancer is a kind of neuroendocrine tumor and the incidence rate is about 20% in all types of lung cancer. The prognosis is poor because of distant metastasis, lymph node metastasis (hilum, mediastinum) in early stage. There were 2 cases of small cell lung cancer in our research with a diameter lower than 3.0 cm and the SUVmax of the 2 cases were 4.71 and 7.93, respectively.

## CONCLUSION

This research showed that the metabolism level of <sup>18</sup>F-FDG was closely related to the pathological features. The <sup>18</sup>F-FDG metabolism level of squamous cell carcinoma, adenocarcinoma was significantly increased and moderate increased, respectively. The <sup>18</sup>F-FDG metabolism level of bronchioloalveolar carcinoma was relatively lower. The statistic analysis of peripheral lung cancer grouped in terms of tumor size showed it was evident positive relative between the size and <sup>18</sup>F-FDG metabolism level of lung cancer. <sup>18</sup>F-FDG PET/CT demonstrates an excellent performance in diagnosing lung cancer. The combination of anatomic and metabolic imaging provides valuable information for the clinic.

## REFERENCES

- Asamura H, Nakayama H, Kondo H, Tsuchiya R, Shimosato Y, Naruke T (1996). Lymph node involvement, recurrence, and prognosis in resected small, peripheral, non-small-cell lung carcinomas: are these carcinomas candidates for video-assisted lobectomy[J]. *J. Thorac. Cardiovasc. Surg.*, 111(6):1125-1134.
- Bunyaviroch T, Coleman RE (2006). PET evaluation of lung cancer[J]. *J. Nucl. Med.* 47(3): 451-469.
- Chen LB, Tong JL, Song HZ, Zhu H, Wang YC (2007). (18) F-DG PET/CT in detection of recurrence and metastasis of colorectal cancer[J]. *World J. Gastroenterol.*, 13(37):5025-5029.
- Even-Sapir E, Parag Y, Lerman H, Gutman M, Levine C, Rabau M, Figer A, Metser U (2004). Detection of recurrence in patients with rectal cancer: PET/CT after abdominoperineal or anterior resection[J]. *Radiology*, 232(3): 815-822.
- Finkelstein SE, Grigsby PW, Siegel BA, Dehdashti F, Moley JF, Hall BL (2008). Combined [(18)F]fluorodeoxyglucose positron emission tomography and computed tomography (FDG-PET/CT) for detection of recurrent, (131)I-negative thyroid cancer[J]. *Ann. Surg. Oncol.*, 15(1):286-292.
- Fischer BM, Olsen MW, Ley CD, Klausen TL, Mortensen J, Højgaard L, Kristjansen PE (2006). How few cancer cells can be detected by positron emission tomography? A frequent question addressed by an in vitro study [J]. *Eur. J. Nucl. Med. Mol. Imaging*, 33(6):697-702.
- Freudenberg LS, Antoch G, Schutt P, Beyer T, Jentzen W, Müller SP, Gorges R, Nowroosian MR, Bockisch A, Debatin JF (2004). FDG-PET/CT in re-staging of patients with lymphoma[J]. *Eur. J. Nucl. Med. Mol. Imaging*, 31(3):325-329.
- Funai K, Yokose T, Ishii G, Araki K, Yoshida J, Nishimura M, Nagai K, Nishiwaki Y, Ochiai A (2003). Clinicopathologic characteristics of peripheral squamous cell carcinoma of the lung[J]. *Ame. J. Surg. Pathol.* 27(7):978-984.
- Gamez C, Rosell R, Fernandez A, Andia E, Arnaiz MD, Cardenal F, Lorenzo C (2006). PET/CT fusion scan in lung cancer: current recommendations and innovations [J]. *J. Thoracic Oncol.* 1( 1): 74-77.
- Koolen BB, Vogel WV, Vrancken Peeters MJ, Loo CE, Rutgers EJ, Valdes Olmos RA (2012). Molecular imaging in breast cancer: from whole-body PET/CT to dedicated breast PET[J]. *J. Oncol.*, 2012: Article ID 438647, 8 pages.
- Schoder H, Yeung HW, Gonen M, Kraus D, Larson SM (2004). Head and neck cancer: clinical usefulness and accuracy of PET/CT image fusion [J]. *Radiology*, 231(1): 65-72.
- Veit-Haibach P, Luczak C, Wanke I, Fischer M, Egelhof T, Beyer T, Dahmen G, Bockisch A, Rosenbaum S, Antoch G (2007). TNM staging with FDG-PET/CT in patients with primary head and neck cancer[J]. *Eur. J. Nucl. Med. Mol. Imaging*, 34(12):1953-1962.

Yoshioka T, Yamaguchi K, Kubota K, Saginoya T, Yamazaki T, Ido T, Yamaura G, Takahashi H, Fukuda H, Kanamaru R (2003).

Evaluation of 18F-FDG PET in patients with advanced, metastatic, or recurrent gastric cancer [J]. *J. Nucl. Med.*, 44(5):690–699.