

*Original Research Article*

# The diagnostic value of magnetic resonance cholangiopancreatography performed with 0.2 tesla low-field open scanner

Ercument Dogen<sup>1</sup>, Bozkurt Gulek\*<sup>2</sup>, Omer Kaya<sup>3</sup>, Gokhan Soker<sup>3</sup>, Mehmet Sirik<sup>4</sup>, Kaan Esen<sup>5</sup> and Ayse Bolat Ucbilek<sup>3</sup>

**Abstract**

<sup>1</sup>Mersin State Hospital Department of Radiology, Mersin, Turkey

<sup>2</sup>Namik Kemal University Department of Radiology, Tekirdag, Turkey

<sup>3</sup>Numune Teaching and Research Hospital Department of Radiology, Adana, Turkey

<sup>4</sup>Adiyaman University Department of Radiology, Adiyaman, Turkey

<sup>5</sup>Mersin University Department of Radiology, Mersin, Turkey

\*Corresponding Author's E-mail: [bozkurtgulek@yahoo.com](mailto:bozkurtgulek@yahoo.com)  
Tel: +90-533-435-4686

**Magnetic Resonance Cholangiopancreatography (MRCP) is a method which is reliably used in the imaging of the pancreatobiliary system. The method utilizes heavily T2-weighted sequences. Thanks to the great advantages of this particular method, the anatomy of the intra and extrahepatic biliary systems can be investigated properly, reliably, and noninvasively, without any administration of contrast media. MRCP is mainly performed with high-field scanners, with field strengths of 1.5 Tesla or greater. In our study, we used a 0.2 Tesla low-field open scanner instead, and we tested the diagnostic efficacy of this magnet, by comparing our results with those obtained by endoscopic retrograde cholangio-pancreatography (ERCP). We administered the three-dimensional fast spin echo (3D FSE) sequence during MRCP imaging. 36 patients who had applied to the Gastroenterology Department of the Numune Teaching and Research Hospital, Adana, Turkey, underwent MRCP examinations in the Radiology Department of the same hospital. The patients were then examined by ERCP, within the next 48 hours. Bile stones were detected in 17, benign strictures were detected in 4, and malignant strictures were detected in another 4, of the 36 patients, with MRCP. These results were compared with those obtained from ERCP, and the overall sensitivity and specificity of MRCP were found to be 96 % and 90.9 %, respectively. These results showed satisfying harmony with those obtained with high-field MR scanners. We came to the conclusion that using low-field open MR scanners in the process of MRCP is a reliable, practical, and easy way in the diagnostic workup of patients with suspected biliary tract pathologies.**

**Keywords:** Low-Field MR, Open MR, MRCP, Magnetic resonance, Imaging, Tesla

## INTRODUCTION

Imaging of the gallbladder and bile ducts and the detection of biliary obstructions or stones is an important part of radiology practice.

Oral cholecystography was the most effective means

of imaging the gallbladder until the invention of ultrasonography (US). Intravenous cholangiography, on the other hand, was in use before the era of cross-sectional and direct interventional imaging of the biliary

system. These modalities have lost their importance due to certain factors such as the hepatic and renal toxicity they caused, the high rate of nondiagnostic examination results that came out after these procedures, and the inability of performing these examinations in the presence of high serum bilirubin levels. Biliary scintigraphy is used in order to demonstrate certain pathological conditions such as acute cholecystitis, segmental obstruction, and postcholecystectomy and biliary-enteric fistula leaks. The biggest disadvantage of biliary scintigraphy is that its anatomic resolution is very low.

The modern primary modalities for the imaging of the gallbladder and the biliary tract are ultrasound (US), computed tomography (CT), and magnetic resonance imaging (MRI). US is the dominant modality in the imaging of the gallbladder. But the capability of US in the demonstration of stones in the extrahepatic biliary system is very low. CT is usually preferred for the evaluation of gallbladder cancers and complicated cholecystitis cases. Due to the ever-increasing capability of multidetector CT (MDCT) imaging, MDCT-cholangiopancreatography has become an effective imaging modality of the biliary system, as an alternative to MR-cholangiopancreatography (MRCP). MDCT-cholangiopancreatography is particularly effective when patients bear some disadvantages which make it impossible for them to undergo MR imaging, such as metallic implants like pacemakers and aneurysm clips.

MRCP is a very effective means of imaging the pancreatobiliary system noninvasively. MRCP utilizes heavily T2-weighted imaging. MRCP makes possible the imaging of the intra- and extrahepatic biliary tree in a speedy and secure manner, without the use of contrast material and with no risk of major complications. With the aid of new sequences under development, contrast enhanced (CE) MRCP, dynamic MRCP, and functional MRCP will become very effective modalities in the imaging of the biliary tract (Chen et al., 2005).

MR technology is constantly undergoing development. One of the most important products of this technologic boom is the open MR technology. Open MR systems are usually low-field scanners and most of them utilize permanent type magnets. These machines possess certain advantages and disadvantages when compared with the closed-bore high-field MR scanners. The major disadvantages of most open systems are their inability to perform advanced imaging techniques such as MR-spectroscopy (MRS) and diffusion and perfusion imaging. Another disadvantage is the longer examination times these machines require. But still these machines possess certain advantages over high-field systems. First of all, these machines do not require cooling systems. They are very economic because they utilize very low amount of energy due to the permanent character of their magnets, they possess very long-lasting magnet homogeneity capacities, they are ideal for children and patients with claustrophobia, and they permit interventions. Because of

the above-mentioned reasons, the use of open MR scanners provide great practicality and advantage in patients who can tolerate longer examination times.

The purpose of this study was to compare the results of low-field MRCP imaging with those of ERCP, and to evaluate the overall diagnostic efficacy of low-field MRCP imaging.

## MATERIALS AND METHODS

36 patients who had applied to the Adana Numune Teaching and Research Hospital with abdominal complaints concerning the biliary system were recruited for this study. All of the patients underwent MRCP and ERCP examinations. The age spectrum of the patients was between 24 and 80 years, and the mean age was 56 years (Figure 1). 24 of the patients were females, and 12 were males (Figure 2).

All of the patients were suspected to have benign or malignant biliary obstruction and or choledocolithiasis, and all of them were patients enlisted for ERCP examinations. The study was approved by the local ethical committee of the hospital and conducted in accordance with the Declaration of Helsinki. All patients gave their full informed consents prior to the study. The patients were asked to fast at least for 5-6 hours prior to the MRCP examinations, with the purpose of maintaining gallbladder filling and stomach emptying, and also not inducing intestinal peristaltic activity. No intravenous (iv) or oral contrast media was used. No iv or intramuscular (im) antiperistaltic drug was administered. The physical examination reviews, medical histories, and biochemical laboratory results of the patients were evaluated prior to the MRCP examinations.

MRCP examinations were performed in a 0.2 T low-field open MR scanner (Airis Mate, Hitachi Medical Industries, Japan). No patient developed claustrophobia. The patients were given thorough information about the procedure, prior to their examinations. No complications developed. The patients were placed in the MR machine supinely, and the examinations were performed during free breathing. The abdomen was wrapped with a band in order to decrease breathing artifacts.

Localizer images were obtained by the administration of T2W gradient echo (GRE) sequences in the sagittal and coronal planes. Localizer sequence parameters were as follows: FOV = 32 cm, TR = 100 ms, TE = 12 ms, FA = 30°, NSA = 1, matrix = 128x256, and slice thickness = 10 mm.

Fast Spin Echo (FSE) 3D MRCP images were obtained over the localizer images. The FOV values changed between 35-45 cm, from patient to patient, whereas the following parameters were used standardly for every patient: TR = 12000 ms, TE = 300 ms, FA = 90°, NSA = 2, matrix = 256x256, and slice thickness = 2 mm.

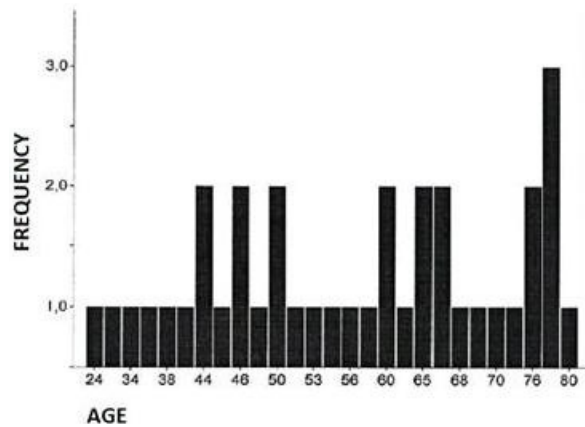


Figure 1. The age distribution of patients



Figure 2. The gender distribution of patients

Heavily T2W axial scans were obtained from every patient in order to demonstrate the level of benign or malignant strictures, external impressions, and intrahepatic bile duct dilatations. The parameters of this sequence were as follows: FOV = 35 cm, TR = 4220 ms, TE = 100 ms, FA = 90°, NSA = 4, matrix = 256x188, slice thickness = 9 mm.

All of the cross-sectional images obtained from the axial, coronal, and sagittal planes were examined thoroughly, and then the maximum intensity projection (MIP) reconstructions were produced and evaluated separately. MIP images are 3D reconstructions which may be rotated in every direction and they resemble direct cholangiographic images. These images make possible the evaluation of the whole biliary tract system on a single image pattern. All of the images obtained were evaluated by 2 experienced radiologists.

The common bile duct (CBD) was assessed as dilated if its diameter was over 7 mm in nonoperated patients, whereas in patients with a history of cholecystectomy and patients over 75, 10 mm was accepted as the threshold. The diameter of the pancreatic duct was measured at its widest segment and measurements over 2 mm were accepted as dilated.

When the anteroposterior diameter of the gallbladder exceeded 4cm on axial T2W images, the gallbladder was evaluated as dilated. Signal-void images in the gallbladder with oval, multifaceted, or irregular formations were evaluated as gallbladder stones. In case

a biliary obstruction was detected, efforts were focused at determining the level and etiology of the obstruction. Positive MRCP findings were accepted as benign in the presence of the following findings: diffuse and concentric narrowing of the wall, diffuse multifocal strictures and focal dilatations in intra and extrahepatic bile ducts, and diverticule-like formations. Focal eccentric thickenings protruding into the lumen distally, and dilating it proximally, were evaluated as malignant biliary obstruction.

All patients underwent ERCP examinations during the first 48 hours following the MRCP procedures. ERCP procedures were done by 2 gastroenterologists, with the presence of a radiologist. Prior to the ERCP procedures, the gastroenterologists gave detailed information to the patients about the procedure itself and its possible complications, and all patients gave their full informed consent in return, concerning the procedure. The ERCP procedures were performed under local anesthesia, and antiperistaltic agents were used when needed. No complications were seen in any of the ERCP procedures.

## RESULTS

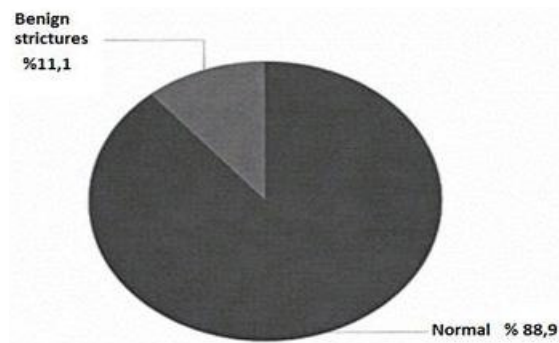
ERCP and MRCP procedures were performed in 36 patients, of whom 24 were females and 12 were males. The ages of the patients ranged between 24 and 80 years, and the mean age was 56 years (Table 1). The

**Table 1.** Numbers of successful ERCP and MRCP procedures

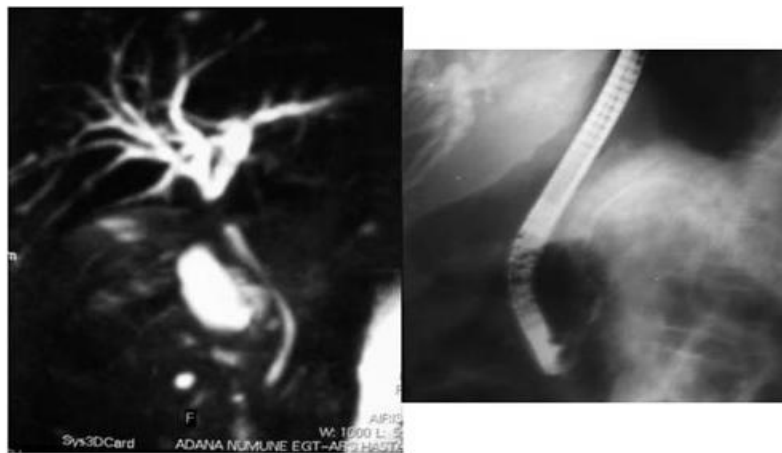
	PATIENTS					
	VALID		INVALID		TOTAL	
	Number	%	Number	%	Number	%
ERCP and MRCP	36	100,0	0	,0	36	100,0

**Table 2.** The ratios showing the capability of MRCP in differentiating benign strictures

		PATIENTS			
		Number	%	Valid %	Total
VALID	Normal	32	88,9	88,9	88,9
	Benign strictures	4	11,1	11,1	100,0
	Total	36	100,0	100,0	



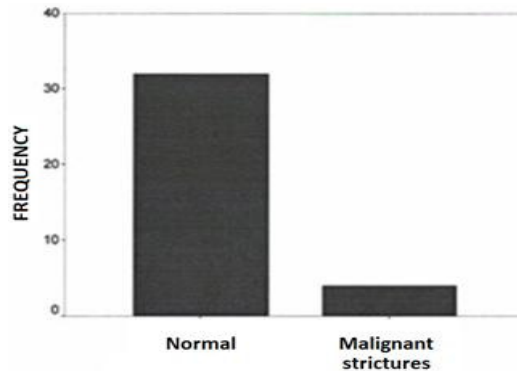
**Figure 3.** The percentages showing the capability of MRCP in differentiating benign strictures. Normal: No benign strictures; Benign Stricture: Demonstrating benign strictures.



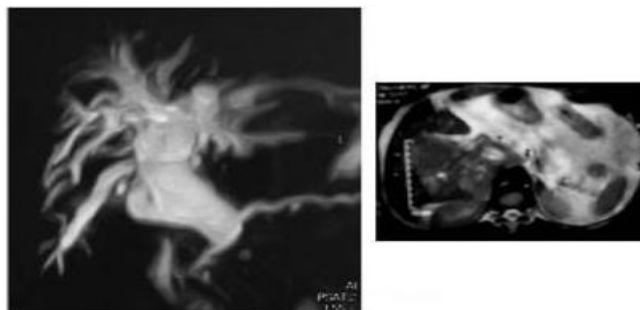
**Figure 4.** Stenotic and dilated segments in the intra and extrahepatic biliary tracts in a female patient of 44 years of age. The image at the left is from the MRCP, and the one at the right is from the ERCP, procedures.

**Table 3.** The ratios of the capability of MRCP in differentiating malignant strictures. Normal: No malignant strictures, Malignant Stricture: Demonstrating malignant strictures.

		PATIENTS			
		Number	%	Valid %	Total
VALID	Normal	32	88,9	88,9	88,9
	Malignant strictures	4	11,1	11,1	100,0
	Total	36	100,0	100,0	



**Figure 5.** The frequencies concerning the capability of MRCP in differentiating malignant strictures. Normal: Number of patients showing no malignant strictures, Malignant stricture: Number of patients demonstrating malignant strictures.



**Figure 6.** Images showing malignant biliary obstruction due to cancer of the pancreatic head. The image on the left is an MRCP view, while the one on the right is a T2W axial MR image.

results are given in the form of tables. Diagnostic images were obtained from all patients.

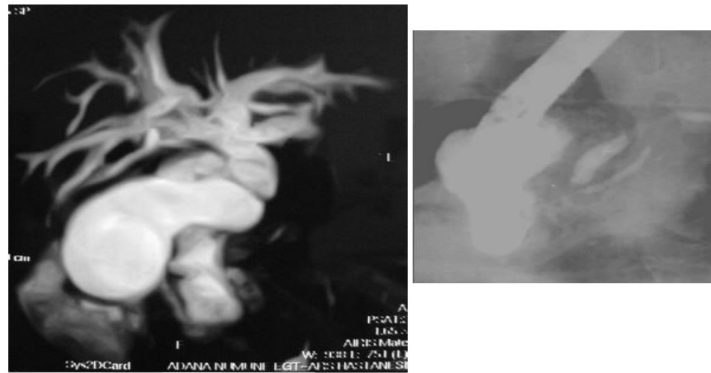
### Benign strictures

MRCP findings such as diffuse concentric strictures, multifocal strictures and dilatations in intra or extrahepatic bile ducts, and associating diverticule-like formations, were all evaluated in favor of benign narrowings. Benign

biliary strictures were detected in 4 patients at MRCP, and these findings were confirmed by ERCP. The ratio of benign strictures was found to be 11.1 % (Table 2, Figures 3 and 4).

### Malignant biliary obstruction

Focal eccentric thickenings protruding into the lumen and leading to dilatations proximally, were evaluated as



**Figure 7.** Malignant biliary obstruction in a patient followed by the diagnosis of metastatic gastric cancer. The image on the left is from the MRCP, while the one on the right is from the ERCP, procedures.

**Table 4.** The ratio of patients who were diagnosed with biliary stones at MRCP

		Patients			
		Frequency	%	Frequency	Total %
Frequency	Normal	19	52,8	52,8	52,8
	Stone	17	47,2	47,2	100,0
Total		36	100,0	100,0	

**Table 5.** Comparison of MRCP with ERCP. n: stone-negative ; p: stone-positive

		ERCP			Total
		negative	positive		
MRCP-stone	negative	Number	18	1	19
		% MR-stone	94,7%	5,3%	100,0%
		% ERCP-stone	94,7%	5,9%	52,8%
	positive	Number	1	16	17
		% MR-stone	5,9%	94,1%	100,0%
		% ERCP-stone	5,3%	94,1%	47,2%
Total		Number	19	17	36
		% MR-stone	52,8%	47,2%	100,0%
		% ERCP-stone	100,0%	100,0%	100,0%

malignant biliary obstruction. Malignant biliary obstructions were detected in 4 patients by MRCP. These diagnoses were confirmed by ERCP (Table 3, Figures 5, 6, and 7).

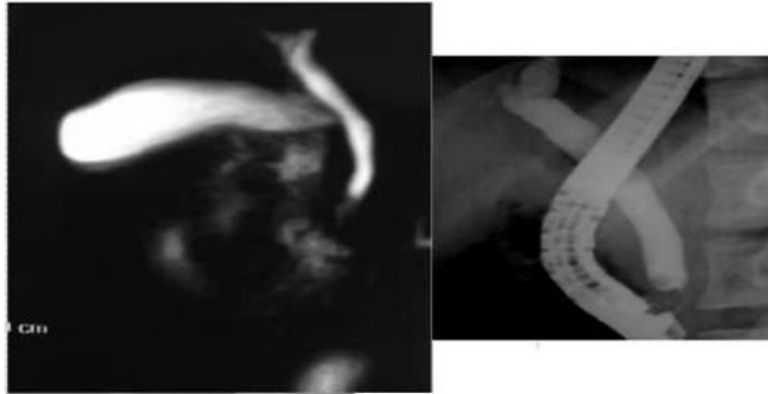
### Biliary stones

Signal-void images in the bile ducts demonstrating round, oval, multifaceted, or irregular shapes, were evaluated as

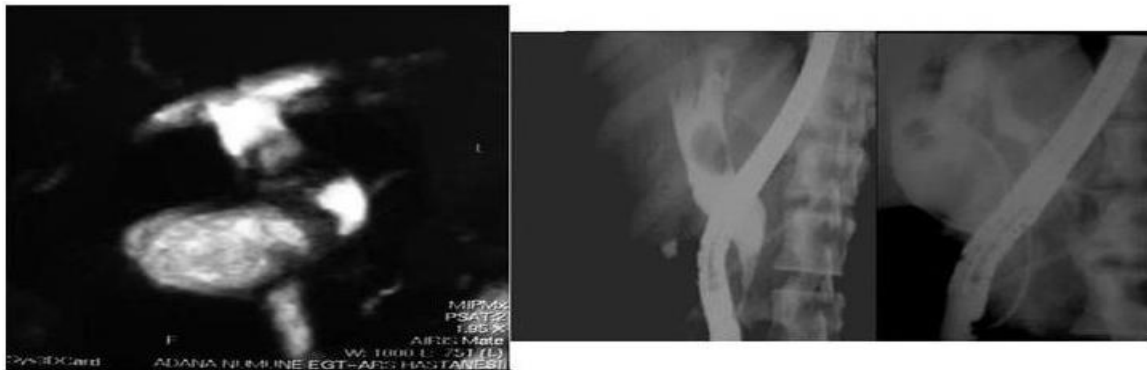stones. 16 of the 17 patients diagnosed with biliary stones at MRCP were confirmed as having stones at ERCP. ERCP demonstrated the presence of a stone in 1 patient who was evaluated as normal at MRCP (Tables 4 and 5, Figures 8 and 9).

### The evaluation of the gallbladder

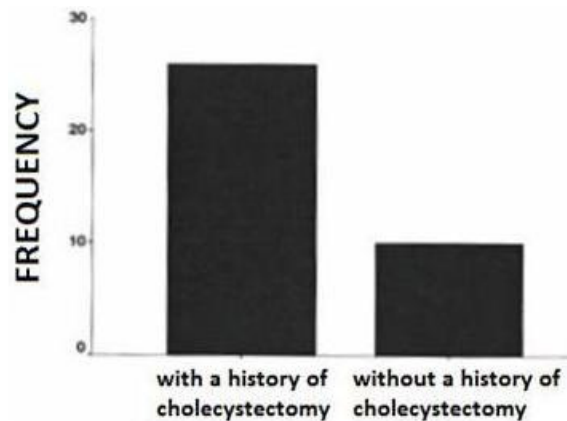
Signal-void images demonstrating round, oval, multifac-



**Figure 8.** Millimetric stone at the distal aspect of the CBD in a female patient of 24 years of age. MRCP image on the left, and ERCP image on the right.



**Figure 9.** The MRCP image on the left and the ERCP image on the right, demonstrate millimetric stones in the CBD which is dilated to 3 cm in diameter. The image on the right shows the balloon dilatation procedure during ERCP.

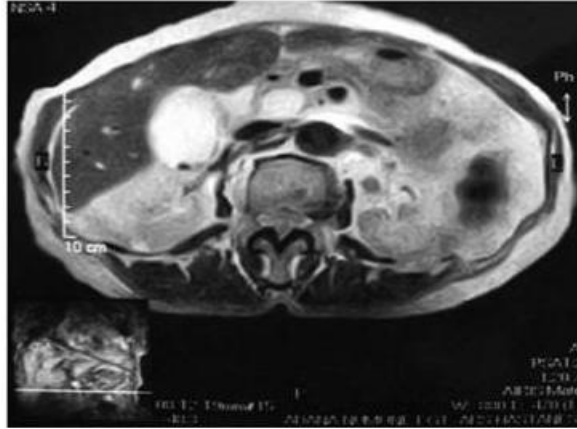

**Figure 10.** Numbers of patients with and without a history of cholecystectomy. There were 10 patients with, and 26 patients without, a history of cholecystectomy.

ted, or irregular shapes, were evaluated as stones. Gallbladder stones were detected by MRCP in 2 patients. 10 patients had a history of cholecystectomy. A choledocal stone was demonstrated in 6 of these patients (Figures 10 and 11).

#### **General evaluation and findings evaluated as normal**

In case there were no narrowed or dilated segments in intra and extrahepatic bile ducts, the finding of a CBD of a diameter of less than 7 mm in patients without a history



**Figure 11.** The gallbladder and its millimetric stone as seen on T2W imaging

**Table 6.** The comparison table of patients evaluated as normal at MRCP and ERCP. N: Negative; P: Positive

		ERCP Normal		Total	
		Positive	Negative		
MRCP Normal	Positive	Number	24	1	25
		% MR Normal	96,0%	4,0%	100,0%
	Negative	% END Normal	96,0%	9,1%	69,4%
		Number	1	10	11
		% MR Normal	9,1%	90,9%	100,0%
		% END Normal	4,0%	90,9%	30,6%
TOTAL	Number	25	11	36	
	% MR Normal	69,4%	30,6%	100,0%	
	% END Normal	100,0%	100,0%	100,0%	

of cholecystectomy, or a CBD of a diameter of less than 10mm in patients with a history of cholecystectomy and patients over 75 years of age, was accepted as normal. The pancreatic duct was accepted as normal when its diameter was below 2 mm. A stone was detected at ERCP in 1 of the 11 patients who were evaluated as normal at MRCP (Tables 6 and 7; Figures 12 and 13).

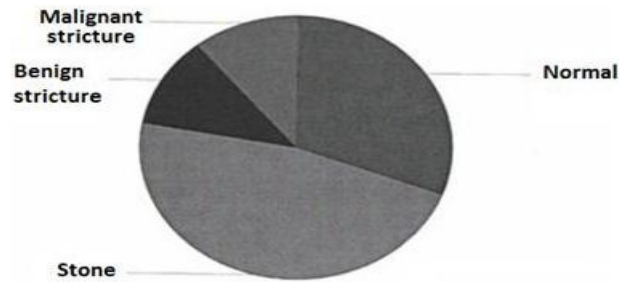
At MRCP, 17 patients were diagnosed with stones, 4 with benign strictures, and 4 with malignant strictures. These results were compared with those from ERCP. By using the 3D FSE method, the sensitivity of MRCP in the detection of the obstructive pathological conditions of the biliary tract was found as 96 %, whereas its specificity was found to be 90.9 %. These rates show similarity with those obtained from high-field MRI systems.

## DISCUSSION

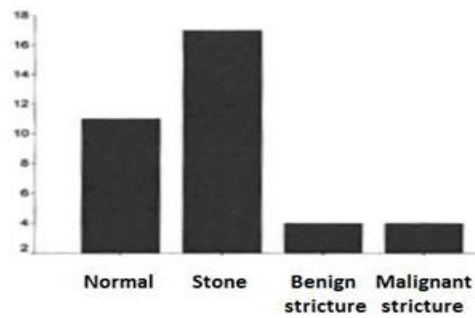
The imaging of the gallbladder and biliary tract, the detection of an obstruction and its level, and the demonstration of stones, is an important part of radiology practice.

There have been important developments in the diagnosis of these pathologies during the last decades, thanks to the breakthroughs in US, CT, and MR technologies.

First, the biliary tract is examined to detect any obstructions. The key point in the diagnostic work-up is the detection of dilated, nondilated, and nonvisualized portions of the biliary tree. In case of an obstruction, efforts are aimed at detecting the level and etiology of the



**Figure 12.** The percentage ratios of the capability of MRCP in differentiating pathological conditions of the biliary tract. Normal 30.6 %, biliary tract stone 47.2 %, benign stricture 11.1 %, malignant stricture 11.1 %.



**Figure 13.** The number of pathological conditions differentiated by MRCP

**Table 7.** The comparative table of MRCP and ERCP

		ERCP				Total	
		Normal	Stone	Malignant	Benign		
MRCP	Normal	Number	10	1	0	0	11
		% MRCP	90.9%	9.1%	.0%	.0%	100.0%
	Stone	Number	1	16	0	0	17
		% ERCP	5.9%	94.1%	.0%	.0%	100.0%
	Malignant	Number	0	0	4	0	4
		% ERCP	.0%	.0%	100.0%	.0%	100.0%
	Benign	Number	0	0	0	4	4
		% ERCP	.0%	.0%	.0%	100.0%	100.0%
	Total	Number	11	17	4	4	36
		% ERCP	30.6%	47.2%	11.1%	11.1%	100.0%

obstructive process (Baron et al., 2002).

Oral cholecystography had been the primary means of imaging of the gallbladder until the 1970s, but later US

took its place and became the fundamental tool of gallbladder imaging. IV cholangiography, on the other hand, was in use prior to the development of cross-

sectional and direct interventional imaging of the biliary system. But iv cholangiography has no use in today's imaging of the biliary tract, mainly due to factors such as hepatic and renal toxicity, high levels of nondiagnostic results, and the inability to perform the procedure in case the serum bilirubin levels are high. Biliary scintigraphy, on the other hand, is useful in the demonstration of acute cholecystitis. This noninvasive modality may also be used to demonstrate biliary drainage, segmental obstruction, and postcholecystectomy and biliary-enteric fistula leaks. The biggest disadvantage of this modality is its very low anatomic resolution (Maglente et al., 1991; Rosenthal et al., 1990; Klingensmith et al., 1982).

Contemporary gallbladder imaging is done by US, CT, and MR. US is the dominant means of imaging the gallbladder. CT is preferred in the evaluation of gallbladder cancers and cholecystitis complications. US is the primary means of imaging of the gallbladder, due to its certain advantages such as its cheapness, speed, noninvasiveness, practicality, and portability. Gallbladder stones constitute the most important indication of gallbladder US; and the sensitivity and specificity of US in this aspect has been reported to be between 95-99 %, in various articles. The positive predictive value (PPV) of US in the diagnosis of acute cholecystitis is 92 %. Extrahepatic biliary ducts are usually visible on US, while intrahepatic ducts do not come into view unless they are dilated. Air in the colon and duodenum make it difficult to image the biliary system.

It has been reported that the specificity of US in the detection of extrahepatic bile duct stones is between 18-70% (Cooperberg et al., 1987; Laing et al., 1998; Cooperberg et al., 1982).

CT is not the primary method in the imaging of the gallbladder because its sensitivity is low (80-85 %), it is more expensive when compared to US, and it utilizes ionizing radiation. But in the diagnostic imaging of gallbladder cancer and the detection of its dissemination, CT is the primary choice. CT is also utilized for the evaluation of complications such as pericholecystic abscesses and perforations. With CT, the presence of a biliary obstruction can be detected with an accuracy of 96-100 %, while this number is 90 % for the detection of the level of the obstruction, and 70 % for the detection of the etiology of the obstruction. Besides, the dissemination of a malignant obstructive lesion can also be evaluated by CT; while CT makes possible the biopsy of the lesion under CT guidance (Goldberg et al., 1978; Baron et al., 1983). CT cholangiopancreatography done by multidetector CT is an imaging modality alternative to MRCP. Especially in the imaging of patients who present certain contraindications to MR imaging such as aneurysm clips, pacemakers, and other metallic implants, CT may be the primary option in biliary tract imaging. The disadvantages of CT are its utilization of ionizing radiation and iv contrast material. In a study in which cholangiopancreatography was performed by multidetec-

tor CT, the etiology of the obstruction was detected with an accuracy of 83 % (Memel et al., 1998; Baron et al., 1997; Ahmetoglu et al., 2004).

The biggest advantage of ERCP is its capability of permitting therapeutic interventions at the same sequence, following the diagnostic procedure. The primary indication of ERCP is the demonstration of the bile ducts, the extrahepatic ones in particular. The biggest disadvantages of ERCP are that it is an invasive modality, and it bears the risk of certain complications such as pancreatitis (5 %) and cholangitis (1-2 %). The risk of perforation is around 1 % in patients who undergo sphincterotomy. A similar risk is present for hemorrhage. This risk increases in coagulopathies and cirrhosis (Rohrmann et al., 1977; Cohen et al., 1996).

Percutaneous transhepatic cholangiopancreatography (PTC) is a very efficient modality for the imaging of the biliary system, by means of opacifying the biliary tree.

By means of PTC, it is possible to opacify and visualize the bile ducts with an accuracy of 100 % when they are dilated, and 80-85 % when they are not. The overall complication rate of PTC is about 3.5 %. The most frequent serious complication is sepsis, with a rate of 1.4%. The rate of biliary leak is 1.45 %, and that of intraperitoneal hemorrhage is 0.35%. Rare complications include pneumothorax, hepatic arteriovenous fistula, allergic reactions against contrast media, and finally, death. There are no contraindications to PTC else than unregulated hemorrhagic diatheses. Ascites makes the procedure more difficult, but it is by no means a certain contraindication (Mueller et al., 1981).

MRCP is an MR technique which is used to image the pancreatobiliary system noninvasively. MRCP utilizes heavily T2W imaging, and enables the fast and secure imaging of the intra and extrahepatic bile ducts without causing any major complications (Dusunceli et al, 2004).

In our study, we utilized the 3D-FSE sequence for MRCP imaging. The signal-to-noise ratio (SNR) and the contrast/noise ratio (CNR) are high in this technique. Thinner slices may be obtained with this sequence. This technique also has the advantage of decreased magnetic susceptibility to certain objects such as surgical clips (Reinhold et al., 1996; Takehare et al., 1994).

Modified FSE sequences with shorter scan times and enhanced image quality have been developed. These are the RARE and HASTE sequences. With HASTE, the examination time has been shortened. But one disadvantage of HASTE is that it necessitates the use of high magnetic field strengths (Yamashita et al., 1997).

MR technology has evolved very fast and one of the developments has been the open MR. Open MR machines generally are low-field scanners, and the one we used was a 0.2 T device. There are certain advantages and disadvantages of low-field MR scanners in comparison to high-field ones. Major disadvantages are the inability to perform certain advanced imaging protocols such as spectroscopy and diffusion and

perfusion imaging, and the long duration of imaging times. Major advantages, on the other hand, may be listed as follows: these machines do not require cooling systems, they operate on a very low consumption of electric energy because they have permanent magnetism, and they possess field homogeneities of very long durations. Besides, the magic angle phenomenon, which is a drawback in MR imaging, is encountered much less with these machines. In addition, an overall general advantage of open systems over closed-bore ones is that these machines are ideal for patients who suffer claustrophobia. Still another advantage is that these systems permit interventions. Due to the aforementioned reasons, the use of open MR systems provides great practicality and advantage over closed-bore ones, especially for patients who suffer claustrophobia (Cevikol et al., 2004).

The FSE sequence is widely used in the practice of MRCP. The sensitivity and specificity of the FSE sequence and its variants in the imaging of choledocholithiasis has been reported to be between 81-100 % and 85-100 %, in various studies performed by Fulcher et al (Fulcher et al., 1999). In a study they performed with 265 patients, Fulcher et al reported that they detected the stones in all of the 106 patients who had choledocholithiasis, with a sensitivity and specificity of 100 % (Fulcher et al., 1998). Zidi et al have reported after a study they performed, that the sensitivity and specificity of MRCP were 57 % and 100 %, for stones smaller than 6 mm (Zidi et al., 1999). In a study done by Becker et al over 108 patients, the results were evaluated by 3 independent validators and the sensitivity and specificity were found to be 88-92 % and 91-98 %, in respect (Becker et al., 1997). A signal-void image in the gallbladder at MRCP with a spheric, oval, multifaceted, or irregular shape is accepted as a stone. In 16 of the 17 patients who were diagnosed with bile duct stones at MRCP in our study, ERCP confirmed the results. In 1 patient who was evaluated as normal according to the MRCP findings, ERCP detected a stone. The sensitivity was 94.10 % and the specificity was 94.70 %, according to the results of our study which was conducted by the 3D FSE MRCP technique. Our results are in harmony with those from the literature.

The sensitivity and specificity of the FSE sequence which is widely used to demonstrate malignant strictures by MRCP has been investigated in various studies. Holzknrecht et al have performed such a study and reported the sensitivity and specificity as 100 % (Holzknrecht et al., 1998). Fulcher et al have reported the sensitivity and specificity of MRCP as 100 % and 97.6 % in a study they performed with 265 patients (Fulcher et al., 1998). Park et al have performed a study on 22 patients who were suspected to have benign or malignant biliary obstructions. The authors found the sensitivity of MRCP as 81 % and the specificity as 70% (Park et al., 2004). In our study, focal eccentric thickenings protruding

into the lumen and causing proximal dilatation were assessed as malignant biliary obstructions. Malignant biliary obstruction was detected by MRCP in 4 patients in our study. These malignant obstructions were confirmed at ERCP. The 3D FSE sequence was utilized at MRCP, and both the sensitivity and specificity were found to be 100 %. The results are compatible with those from the literature. It was observed that MRCP had a very important role in these patients as a guide prior to an intervention.

The sensitivity and specificity of the FSE sequence which is widely used to demonstrate benign strictures by MRCP has been investigated in various studies. Fulcher et al have done another study on 102 patients. The results of this study were evaluated by 2 independent radiologists and the sensitivity and specificity were found as 85-88 % and 92-97 %, respectively (Fulcher et al., 2000). Ernst et al reported the sensitivity and specificity of MRCP to be 100 %, in a study they performed with 9 patients (Ernst et al., 1998). Kim et al have shown that the combination of conventional MR sequences with MRCP increase the accuracy of the procedure (Kim et al., 2000). In our study, the dilated and narrowed zones of the duct were visualized at MRCP. Diffuse concentric narrowing of the wall at the transitional zone, diffuse multifocal strictures in intra and extrahepatic bile ducts, focal dilatations, and diverticule-like formations, were all assessed in favor of benign strictures. Benign biliary strictures were detected in 4 patients by MRCP in our study, and these findings were confirmed at ERCP. The sensitivity and specificity of MRCP performed by the 3D FSE sequence was found to be 100 %, each. The results were competent with those from the literature.

In the absence of any narrowed or dilated bile ducts, the MRCP findings were accepted within normal limits if the diameter of the CBD was below 7mm in patients without, and below 10 mm in patients with, a history of cholecystectomy, and also in patients over 75 years of age. The pancreatic duct was accepted normal when its diameter was under 2 mm. Of the 36 patients who were evaluated by MRCP, 17 had stones, 4 had benign strictures, and 4 had malignant strictures. The results were compared with those obtained from ERCP. ERCP disclosed the presence of a bile duct stone in 1 of the 11 patients who were assessed as normal according to the MRCP findings. The sensitivity and specificity of MRCP in demonstrating obstructions of the biliary tract were found as 96 % and 90.9 %, respectively. Atherton et al have found the sensitivity and specificity of MRCP as 89 % and 92 %, respectively (Atherton et al., 1999). Fulcher et al have done a study with 182 patients and reported the sensitivity and specificity of MRCP as 100 % (Fulcher et al., 1998). Barish et al have reported the sensitivity and specificity of MRCP to be 87 % and 100 %, respectively, in the demonstration of biliary strictures (Barish et al., 1995). Guibaud et al have found the sensitivity of MRCP

as 91 %, while they reported the specificity of the modality as 100 % (Guibaud et al., 1995).

At the end of our study, we would like to emphasize that MRCP is an MR technique used to evaluate the pancreatobiliary system noninvasively. The technique utilizes heavily T2W imaging. With MRCP, the intra and extrahepatic bile ducts and the pancreatic duct can be visualized in a fast and reliable way, without the use of contrast material and without any major complications. The results of various studies have shown that the accuracy of MRCP reaches 100 % in the demonstration of biliary obstructions and their levels. This accuracy is reported to be between 85-100 % when it comes to the demonstration of the lesions causing these obstructions.

Various methods may be utilized in the imaging of the biliary system. But the method of choice must be determined according to the patient's needs and the therapy planned. It is the advantage of PTC and ERCP that the direct visualization of the biliary system and possible interventions may be done in the same session in an all-in-one manner. Their disadvantage, on the other hand, is that they are invasive modalities and they possess the risk of certain complications. Constantly developing MRCP applications have led to a fall in the number of ERCP and PTC procedures. It is also important to know that MRCP is also a guide for possible interventions. In certain conditions when MR is contraindicated, such as the presence of aneurysmal clips and pacemakers, CT cholangiography may be utilized.

Open MR systems like the one we used in our study have certain major advantages. First of all, they are cheap to install and operate. In addition, they make it possible to examine kids and claustrophobia patients, and they permit interventions. A major disadvantage of these machines is that the examination time must be prolonged due to the low-field strengths.

In our study, the 3D FSE technique was utilized for the MRCP performances. The results obtained from these examinations were compared with those from the ERCP procedures, and it was seen that MRCP results were very accurate. The overall results were then compared with those reported in the literature and obtained from closed-bore high-field systems, and it was seen that the results showed significant parallelism (Hoeffel et al., 2006).

As a conclusion, it must be emphasized that MRCP examinations done with low-field-strength MR systems are good for the evaluation of the pathological conditions of the biliary system. These MR systems are reliable and practical, they provide comfort, and they are cheap to install and operate.

## REFERENCES

Ahmetoglu A, Kosucu P, Kul S, DinçH, Sari A, Arslan M, Alhan E, Gümele RH (2004). MDCT cholangiography with volume rendering for the assessment of patients with biliary obstruction. *Am J Roentgenol.* (183):1327-1332.

- Atherton JC (1999). MRCP and the diagnosis of suspected bile duct obstruction. *Gut.* (44): 765.
- Barish MA, Yuçel EK, Soto JA, Chuttani R, Ferrucci JT (1995). MR cholangiopancreatography: efficacy of three dimensional turbo spin-echo technique. *AJR.* (165):295-300.
- Baron RL (1997). Diagnosing choledocholithiasis: how far can we push helical CT? *Radiology.* (203):601-603.
- Baron RL, Stanley RJ, Lee JKT (1983). Computed tomographic features of biliary obstruction. *AJR.* (140):1173-1178.
- Baron RL, Tublin ME, Peterson MS (2002). Imaging the spectrum of biliary tract disease. *Radiol Clin North Am.* (40):1325-54.
- Becker CD, Grossholz M, Becker M, Mentha G, de Peyer R, Terrier F (1997). Choledocholithiasis and bile duct stenosis: diagnostic accuracy of MR cholangiopancreatography. *Radiology.* (205):523.
- Cevikol C ve ark (2004). Meniskus yırtıklarının saptanmasında düşük (0.35 T) ve yüksek (1.5 T) Tesla MRG cihazlarının tanısal degeri. *Türk Tanısal ve Girişimsel Radyoloji Dergisi.* (10): 316-319.
- Chen JS, Yeh BM, Wang ZJ, Roberts JP, Breiman RS, Qayyum A, Coakley FV (2005). Concordance of second-order portal venous and biliary tract anatomies on MDCT angiography and MDCT cholangiography. *AJR.* (184):70-74.
- Cohen SA, Siegel JH, Kasmin FE (1996). Complications of diagnostic and therapeutic ERCP. *Abdom Imaging.* (21):385-394.
- Cooperberg PL, Gibney RG (1987). Imaging of the gallbladder. (163):605-613.
- Cooperberg PL, Golding RH (1982). Advances in ultrasonography of the gallbladder and biliary tree. *Radiol Clin North Am.* (20):611-633.
- Dusunceli E, Erden A, Erden G (2004). Biliyer sistemin anatomik varyasyonları: MRKP bulguları. *Türk Tanısal ve Girişimsel Radyoloji Dergisi.* (10):296-303.
- Ernst O, Asselah T, Sergent G (1998). MR cholangiography in primary sclerosing cholangitis. *AJR.* (171):1027-1030.
- Fulcher AS, Turner MA, Capps GW (1999). MR cholangiography: technical advances and clinical applications. *Radiographics.* (19):25-44.
- Fulcher AS, Turner MA, Capps GW, Zfass AM, Baker KM (1998). Half-Fourier RARE MR cholangiopancreatography: experience in 300 subjects. *Radiology.* (207):21-32.
- Fulcher AS, Turner MA, Franklin KJ (2000). Primary sclerosing cholangitis: evaluation with MR cholangiography, a case-control study. *Radiology.* (215):71-80.
- Goldberg HI, Filly RA, Korobkin M (1978). Capability of CT body scanning and ultrasonography to demonstrate the status of the biliary ductal system in patients with jaundice. *Radiology.* (129):731-737.
- Guibaud L, Bret PM, Reinhold C, Atri M, Barkun AN (1995). Bile duct obstruction and choledocholithiasis: diagnosis with MR cholangiography. *Radiology.* (197):109-115.
- Hoeffel C, Azizi L, Lewin M, Laurent V, Aubé C, Arrivé L, Tubiana MJ (2006). Normal and pathologic features of the postoperative biliary tract at 3D MR cholangiopancreatography and MR imaging. *Radiographics.* (26):1603-1620.
- Holzknacht N, Gauger J, Sackmann M (1998). Breath-hold MR cholangiography with snapshot techniques: prospective comparison with endoscopic retrograde cholangiography. *Radiology.* (206):657-664.
- Kim MJ, Mitchell DG, Ito K, Eric K (2000). Outwater biliary dilatation: differentiation of benign from malignant causes-value of adding conventional MR imaging to MR cholangiopancreatography. *Radiology.* (214):173.
- Klingensmith WC, Kuni CC, Fritzberg AR (1982). Cholescintigraphy in extrahepatic biliary obstruction. *AJR.* (139):65-67.
- Laing FC (1998). The gallbladder and bile ducts. In: Rumack CM, Wilson SR, Charboneau JW (Eds): *Diagnostic Ultrasound* (2nd Ed). St. Louis: CV Mosby: 175-224.
- Maglante DDT, Torres WE, Laufer I (1991). Oral cholecystography in contemporary gallstone imaging: a review. *Radiology.* (178):49-58.
- Memel DS, Baffe DM, Semelka RC (1998). The biliary tract. In: Lee JKT, Sagel SS, Stanley RJ, et al (Eds): *Computed Body Tomography with MRI Correlation* (3rd Ed). Philadelphia: Lippincott-Raven:779-844.

- Mueller PR, Harbin WP, Ferrucci JT Jr (1981). Fine needle transhepatic cholangiography: reflections after 450 cases. *AJR*. (136):85-90.
- Park MS, Kyoung K T, Kyoung WK, Park SW, Lee J, Kim JS, Lee JH, Kim KA, Kim AY, Kim PN, LeeMG, Ha HK (2004). Differentiation of extrahepatic bile duct cholangiocarcinoma from benign stricture: findings at MRCP versus ERCP. *Radiology*. (233):234-240.
- Reinhold C, Bret PM (1996). Current status of MR cholangiopancreatography. *AJR*. (166):1285-1295.
- Rohrman CA Jr, Ansel HJ, Ayoola EA (1977). Endoscopic retrograde intrahepatic cholangiogram: radiographic findings in intrahepatic disease. *AJR*. (128):45-52.
- Rosenthal SJ, Cox GG, Wetzel LH (1990). Pitfalls and differential diagnosis in biliary sonography. *Radiographics*. (10):285-311.
- Takehara Y, Inohara K, Tooyama N (1994). Breath-hold MR cholangiopancreatography with a long echo-train fast spin echo sequence and a surface coil in chronic pancreatitis. *Radiology*. (192):73-78.
- Yamashita Y, Abe Y, Tang Y, Urata J, Sumi S, Takahashi M (1997). In vitro and clinical studies of image acquisition in breath-hold MR cholangiopancreatography: single-shot projection technique versus multislice technique. *Am J Roentgenol*. (168): 1449-1454.
- Zidi SH, Prat F, Le Guen O, Rondeau Y, Rocher L, Fritsch J, Choury AD, Pelletier G (1999). Use of magnetic resonance cholangiography in the diagnosis of choledocholithiasis: prospective comparison with a reference imaging method. *Gut*. (44):118-122.