

Case Report

Left-sided gallbladder; an incidental finding during laparoscopic cholecystectomy

Ümit Sekmen^{*1}, Özdal Ersoy² and Melih Paksoy

Abstract

AcıbademFulya Hospital,
Department of General Surgery

¹DikilitaşMah. No: 23 34349,
Beşiktaş -Istanbul/Turkey

²AcıbademFulya Hospital,
Department of Gastroenterology

*Corresponding Author E-mail:
usekmen@yahoo.com
Tel: +90 212 306 45 67; +90 532
651 10 56

A left-sided gallbladder is a rarely seen anomaly of gallbladder. The location is on the left side of the round ligament. This anatomic anomaly may mostly diagnose intraoperatively. We report on a case of left-sided gallbladder discovered incidentally during laparoscopic cholecystectomy, and the preoperative ultrasonography, computed tomography and MR could not detect the anatomic variation obviously. When you diagnose this anomaly intraoperatively, you may need to reposition the trocars and also should be careful about anatomic variations of biliary system. We try to discuss to find out the best approach to perform laparoscopic cholecystectomy and avoid any iatrogenic injury in case of left sided located gall bladder diagnosed intraoperatively.

Keywords: Left-sided gallbladder, Laparoscopic cholecystectomy, Trocar sites.

INTRODUCTION

A left-sided gallbladder (LSG) is a gallbladder located on the left side of the round ligament instead of the right side, which is its common location. This anatomic anomaly firstly described by Hochstetter in 1856 (Hochstetter, 1886). The reported incidence ranges between 0.1% and 1.2% (Idu et al., 1996; Nagai et al., 1997). The present case report demonstrates a case of LSG identified during laparoscopic cholecystectomy. We tried to discuss the different forms of LSG and to find out best surgical approach to avoid injury to any neighboring structure.

CASE REPORT

A 40-year-old Jewish male presented to emergency department with a 2-day history of acute epigastric pain that disseminating to all upper quadrants of abdomen. He was also suffering from vomiting. His blood results showed that white blood cell count was 18.000 /mm³, amylase was 1200 U/dl, lipase was 960 U/dl, and the other parameters such as glucose, bilirubin, alkaline phosphatase, alanine transferase, and gamma-glutaryl transferase were in the normal range.

The computed tomography and ultrasonography detected acute eudematous pancreatitis with normal gall

bladder and biliary tree. But in magnetic resonance imaging of upper abdomen, we found out microcalculi in gall bladder. So we diagnosed as acute biliary pancreatitis and decided laparoscopic cholecystectomy after subsiding of acute inflammatory attack so after 3 days we performed the operation.

First we inserted the umbilical trocar (10mm) we could not see the gall bladder in its normal anatomic location. Then we inserted second trocar (5mm) through on the right subcostal front axillary line. We had chance to elevate the liver and we realized the anatomic variation. Second port helped us to elevate and pull the gallbladder upward. We put new two 5 mm trocars through on midclavicular line of left subcostal region. Surgeon and the assistant were both on the left side of patient and after reposition of patient to reverse trandelenburg, wide view of gallbladder and Callot's triangle were created. **Figure 1** demonstrates the laparoscopic view of anatomic anomaly of gall bladder.

After dissecting Callot's triangle, we identified the cystic duct, the common hepatic duct, choleduct and cystic artery. We created safe anatomic view to prepare cystic duct and artery. After clipping and cutting the cystic duct and the cystic artery, the gallbladder was excised as usual. There was no technical difficulty during the

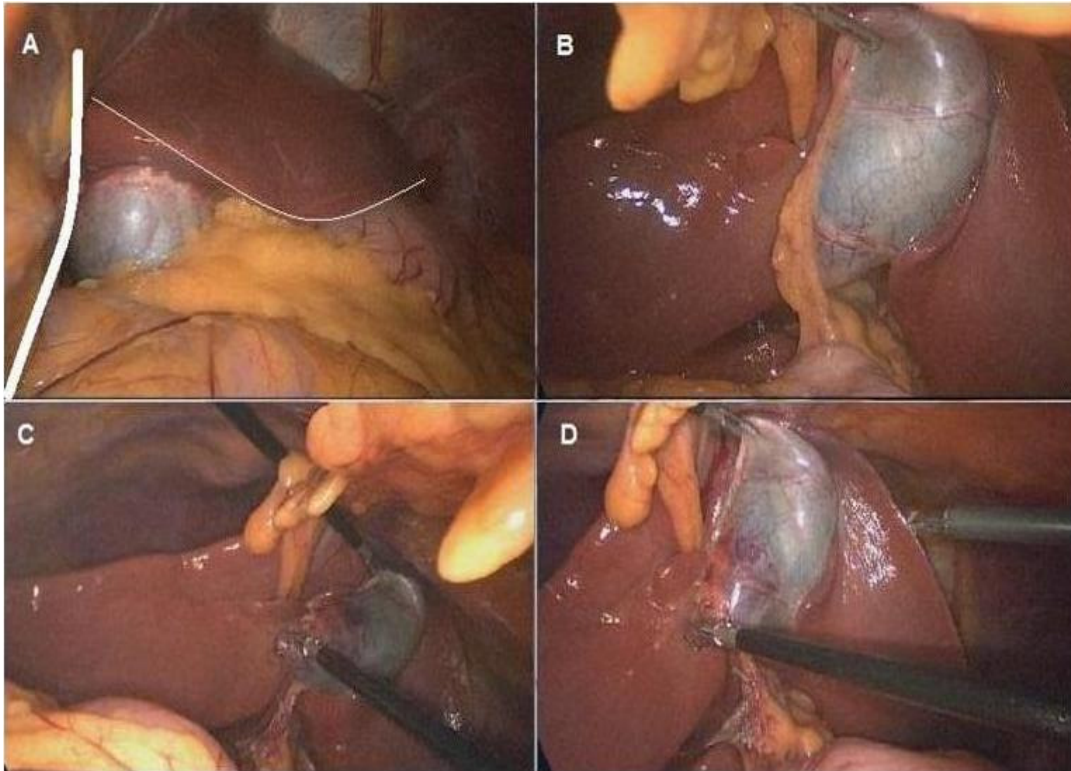


Figure 1. Intraoperative view of gall bladder located under left lobe and medial to round ligamentum of liver (A: white curved line surrounds both falciform ligamentum and medial margins of left lobe)

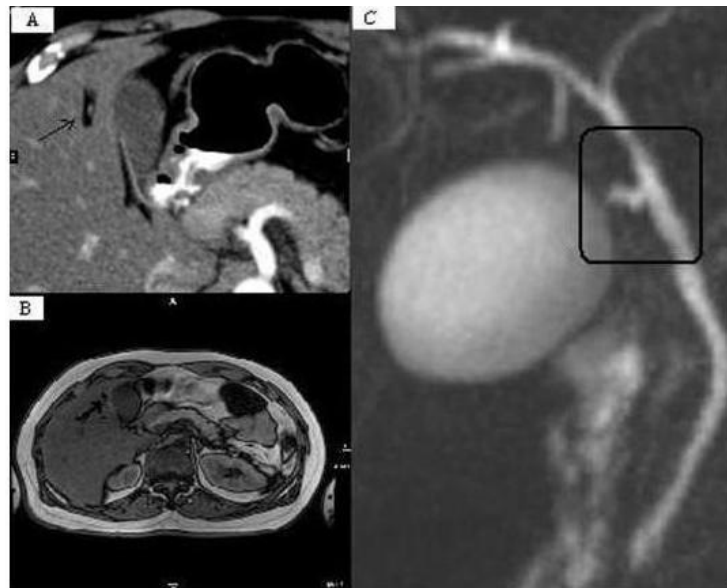

Figure 2. Preoperative radiological imaging of upper abdomen of patient; black arrows show round ligamentum of liver where the gallbladder is located medial to it (A: Computed Tomography, B: Abdominal Magnetic Resonance Imaging) and MRCP (C) shows normal anatomic joining of cystic duct to hepatic duct.

operation and it took about 40 minutes to finish the operation. The patient recovered without any complica-

tion and was discharged on the first postoperative day.

DISCUSSION

Left-sided gallbladder is an anatomic variation. We mostly see gallbladder in lateral side of round ligament. But rarely we see gallbladder medial to round ligament (<1%) (Si-Youn and Poong-Man, 2008). It can be still near to right lobe or to left lobe. If it is located on the left lobe it's called true left sided gallbladder. There are two subvariation in such cases. Cystic duct may join to hepatic duct from right or left side (Hsu et al., 2007; Ikoma et al., 1992). In our case, cystic duct join to hepatic duct as it joins through its normal anatomic route. (Figure 2)

Because the risk of co-existence of left-sided gallbladder and the anomalies of cystic duct, we should keep in mind the risk of cystic duct anomaly of patients with LSGB, to avoid any injury to biliary tree and vessels during surgery (Hsu et al., 2007; Ikoma et al., 1992). Hunter et al (Hunter, 1993) suggested that the preparation and clipping of the cystic duct should be performed as nearly as possible to the infundibulum, after the surrounding tissue is stripped down.

Recent studies suggest that routine ultrasonography in patients with gallstone disease often fail to make the diagnosis of LGB disease in the majority of cases. Even MRI and computed tomography could not detect this anatomic variation in our patient, the diagnosis was made only at the time of surgery, despite repeated radiological investigations as mentioned in another studies. We analyzed the radiologic imaging retrospectively, and found out the anatomic variation of gall bladder, as it located medial to round ligamentum. (Figure 2)

Knowledge of the location of the gallbladder is of great importance for the surgeon, particularly when cholecystectomy or other biliary or hepatic surgery is to be performed (Strong et al., 2013; Alharthi et al., 2012; Zografos et al., 2009).

The notification of anatomic variation is important for positioning of trocars. We may have chance to avoid using extra trocar and trocar sites. It is really important choosing left midclavicular line for two trocars to get easy access for making gall bladder dissection securely and

finalizing the surgery laparoscopically.

CONCLUSION

Left-sided gallbladder is a rare operative finding. Preoperative imaging may not detect the anatomic variations. The recognition of them is important when performing cholecystectomy to avoid injury to the biliary tree. Laparoscopic intervention can be applied safely through the new port sites.

REFERENCES

- Alharthi S, Bernon M, Krige JE (2012). Beware the left-sided gallbladder. *S Afr J Surg.* Jul 11;50(3):88-9
- Hochstetter F (1886). Anomalien der pfortader und der nabelvene in verbindung mit defect oder linkslage der gall-en-blase. *Arch AnatEntwickl.*;369-384.
- Hsu SL, Chen TY, Huang TL, et al., (Provide names of other authors) (2007). Left-sided gallbladder: its clinical significance and imaging presentations. *World J Gastroenterol.*; 13:6404-6409.
- Hunter LG (1993). Exposure, dissection and laser versus electrosurgery in laparoscopic cholecystectomy. *Am J Surg.*;165:492– 496.
- Idu M, Jakimowicz J, Iuppa A, Cuschieri A (1996). Hepatobiliary anatomy in patients with transposition of the gallbladder: implications for safe laparoscopic cholecystectomy. *Br J Surg.*; 83:1442–1443.
- Ikoma A, Tamaka K, Hamada N (1992). Left sided gallbladder with accessory liver accompanied by intra-hepatic chol- angiocarcinoma. *J Jpn Surg Soc.*;93:434-436.
- Nagai M, Kubota K, Kawasaki S, Takayama T, Bandai Y, Makuuchi M (1997). Are left-sided gallbladders really located on the left side? *Ann Surg.*;225:274–280.
- Si-Youn R, Poong-Man J (2008). Left-sided gallbladder with right-sided ligamentum teres hepatis: rare associated anomaly of exomphalos. *J Pediatr Surg.*;43:1390-1395.
- Strong RW, Fawcett J, Hatzifotis M, Hodgkinson P, Lynch S, O'Rourke T, Slater K, Yeung S (2013). Surgical implications of a left-sided gallbladder. *Am J Surg.* Jul;206(1):59-63.
- Zografos GC, Lagoudianakis EE, Grosomanidis D, Koronakis N, Tsekouras D, Chrysikos J, Filis K, Manouras A (2009). Management of incidental left-sided gallbladder. *JSLs.* Apr-Jun;13(2):273-5.