

Case Report

Encephalopathy related to Idiopathic Hypereosinophilic Syndrome: A case report and review of the literature

Sana Ben Amor^{1*}, Ibtissem Hasni Bouraoui², Anis Hassine¹, Nadia Zouari¹, Amina Bouatay³,
Anissa Khefifi¹, Nadia Mama², Moncef Kortas³, Kalthoum Graeiss Tlili² and
Sofien Benammou¹

Abstract

¹Neurology Department, University Sahloul hospital, Sousse, Tunisia

²Imaging Department, University Sahloul Hospital, Sousse, Tunisia

³Haematology's Laboratory, University Hospital Farhat Hached, Sousse, Tunisia

*Corresponding Author's E-mail:
kaffelsana@yahoo.fr
Tel: 0021621688336
Fax: 0021673367451

Idiopathic hypereosinophilic syndrome (IHS) is characterized by persistent hypereosinophilia (>1500/ mm³ for at least 6 months duration) with evidence of end-organ damage. It should be considered only after the exclusion of all other causes of hypereosinophilia. It could be revealed by encephalopathy. In this case, radiological features of cerebral magnetic resonance imaging (MRI) could contribute to the early diagnosis. We report a 33-year-old man presented to the Neurological Department with an acute altered status mental and paraparesis, which had appeared four weeks before. Eosinophils in repeated blood tests were more than 1500/mm³. FLAIR MRI images showed a typical distribution of multiple lesions in the deep and sub cortical white and gray matter. Diffusion weighted images show multiple high signals in the border zone which was high or low in the apparent diffusion coefficient map image. All other secondary causes of hypereosinophilia were ruled out. The evolution was marked by a dramatic response to steroids with improvement of eosinophilia, brain function and cerebral MRI findings. This case suggests that HIS should be considered when other causes of vascular lesions in cerebral MRI are ruled out. We highlight the necessity of introducing corticosteroids precociously in order to improve prognosis.

Keywords: Cerebral MRI, Corticosteroids, Encephalopathy, Hyperesiniphilic syndrome, Prognosis

INTRODUCTION

Idiopathic hypereosinophilic syndrome (IHS), as defined by Chusid and co-workers, is characterized by persistent hypereosinophilia (>1500/ mm³ for at least 6 months duration) with evidence of end-organ damage. It should be considered only after the exclusion of all other causes of hypereosinophilia (Lee and Ahn, 2014). The main neurological complications of IHS are encephalopathy, polyneuropathy, and thromboembolic or hemorrhagic disorders (Kono and Itoh, 2009). In case of encephalopathy, it was reported that an altered status mental is the most significant predictor of poor outcome but the early corticosteroids administration may be beneficial (Lee and Ahn, 2014). The radiological features of cerebral magnetic resonance imaging (MRI) in patients

with HIS- related encephalopathy could contribute to the early diagnosis. There are few reports describing radiological findings (Kwon et al., 2001; Lee et al., 2009). We report a case of HIS-revealing encephalopathy showing abnormal findings in cerebral MRI with clinical and radiological improvement after corticosteroids administration.

Case report

A 33-year-old man, who was previously in good health, presented to the Neurological Department with an acute altered status mental and gait disturbance, which had

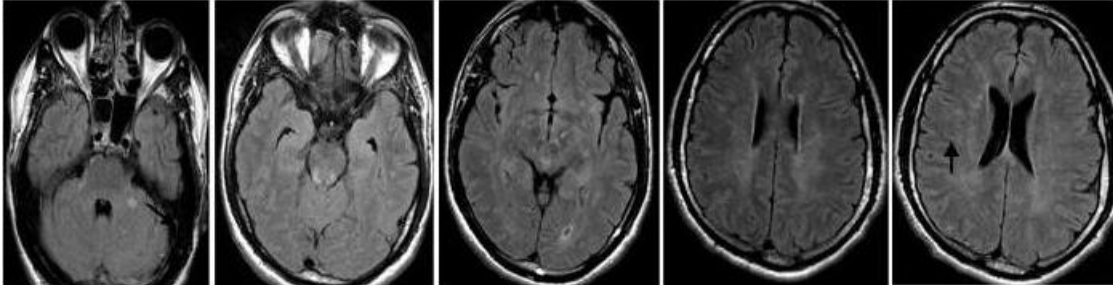


Figure 1. Brain fluid-attenuated inversion recovery (FLAIR) MRI showing multiple deep and subcortical white matter scattered medium-sized lesions in deep and subcortical white matter and midbrain with arterial involvement.

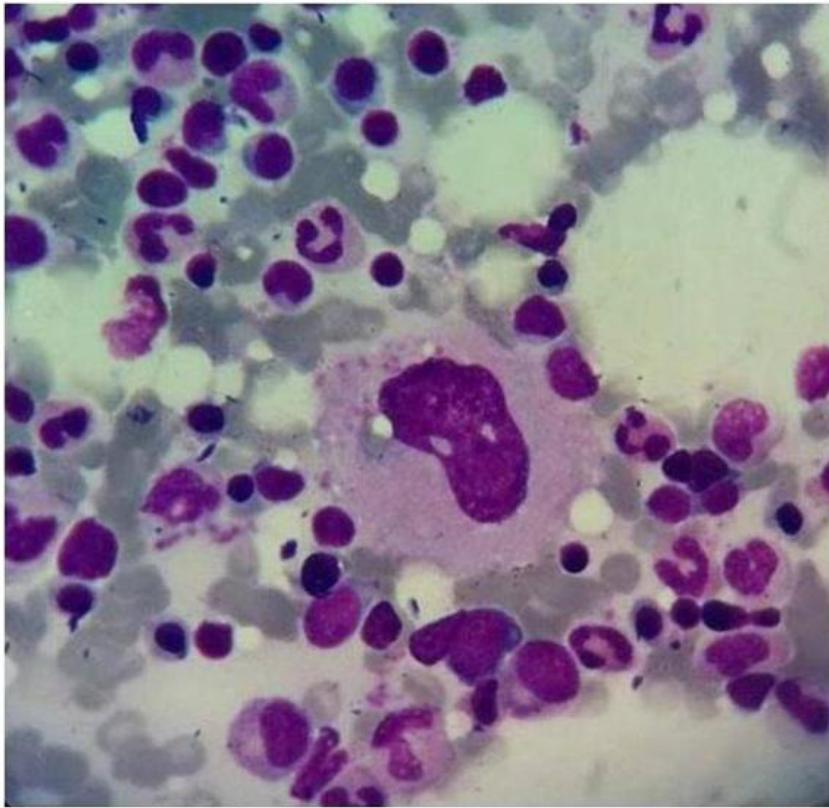


Figure 2. Hematoxylin-eosin stain, 100. Bone marrow biopsy specimen show normal cellularity without excess of blast and a good differentiation of cell lines.

appeared four weeks before. He smoked approximately 4 cigarettes a day and drank little alcohol. The patient reported previous cannabis use but denied any recent use. On admission, the neurological examination showed paraparesis and pyramidal syndrome in both lower limbs. There was impairment in orientation, memory and calculation. The cranial nerve, cerebellar testing and upper extremity motor and sensory examinations were normal.

FLAIR MRI images showed a typical distribution of multiple lesions in the deep and subcortical white and gray matter. Multiple tiny to small lesions were detected

in the midbrain, cerebellum, left thalamus, and both border zones. Multiple high signals in the subarachnoid space without abnormalities in T2* eliminate hemorrhage and show small arteries involvement. Diffusion weighted images show multiple high signals in the border zone which was high or low in the apparent diffusion coefficient map image. A Gadolinium injection did not reveal any enhancement (Figure 1).

The laboratory tests revealed the serum WBC count during that time was $9390/\text{mm}^3$ (reference range, 4500-11000) with 21.1% eosinophils (reference range, 1-3); total eosinophil count, $1980/\text{mm}^3$ (reference range, 0-

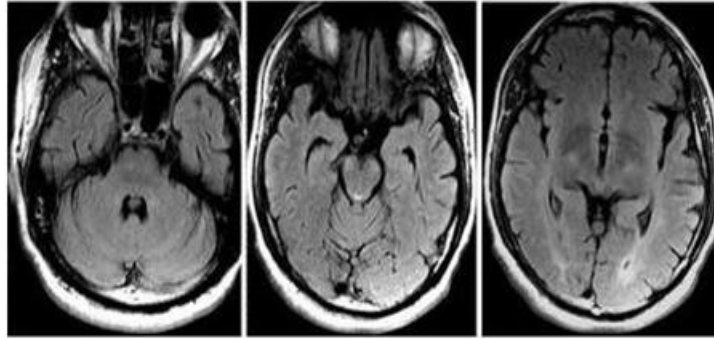


Figure 3. The second brain FLAIR MRI showing disappearance of most lesions

450); serum immunoglobulin E (IgE): 43 IU/mL (reference <120IU/ml). Hypereosinophilia was present in another blood test performed three months before admission. Common causes of increased eosinophil count were excluded. The serological tests of blood and CSF (for cytomegalovirus, herpes simplex virus, varicella-zoster virus, human herpesvirus 6 and enterovirus, brucellosis, lyme disease) were all negative. Blood and urine toxicology screens were negative. Liver and kidney functions tests, electrolytes, cardiac enzymes, serum glucose, blood coagulation profile and erythrocyte sedimentation rate were within normal limits. Anti-neutrophil cytoplasmic antibodies, anti-nuclear antibodies, and lupus cells were negative. Human immunodeficiency virus antibodies were negative. Neuron-specific enolase, carcino-embryonic antigen, alpha fetoprotein, and carbohydrate antigen were also normal. Stool examination was negative for parasite infestation.

The cerebrospinal fluid (CSF) analysis showed one white blood cell/mm³, without any red blood cells, 3.8 mmol/l glucose (serum glucose =5.7mmol/l), and 1.5 g/l protein (normal range, 0.2-0.35 g/l).

A chest, abdomen and pelvis (CAP) scan was normal. A transcranial Doppler evaluation showed normal blood flow velocity in the carotid and vertebral arteries. A cardiac workup, including transthoracic echocardiography (TTE) was normal.

The bone marrow aspiration revealed hypercellular marrow with predominant eosinophil precursors, a normal megakaryotype, normal maturation of the myeloid (M) and erythroid (E) series, no excess of blast (Figure 2). There was no evidence of haematological malignancy. The patient also underwent a skin biopsy. There was no histopathological evidence of vasculitis. HES diagnosis was made after ruling out other causes of increased eosinophil count. He was treated with methylprednisolone pulse therapy (1g/day, 3 days) followed by oral steroids prednisolone (2mg/kg/day) for three months. Prednisolone was maintained at low dose (10 mg/day) during one year. Six months later, eosinophils number

decrease to the normal range. The patient reported clinical improvement. A follow-up MRI demonstrated the decrease and disappearance of the lesions (Figure 3).

DISCUSSION

We reported a case of HIS-related encephalopathy based on clinical findings, biological results and radiological examination. The criteria for IHS diagnosis, defined by Chusid and co-workers include three points (Kono and Itoh, 2009; Kwon et al., 2001; Lee et al., 2009). First, the patient must have high a number of peripheral blood eosinophils (>1500 cells/mm³) for more than six months. Second, we must find signs and symptoms of end-organ involvement with eosinophil tissue infiltration/injury. Third, secondary causes of eosinophilia must be ruled out. In our patient, the common causes of increased eosinophil count, such as hematological diseases, parasitic infections, allergic diseases, drug reactions, autoimmune disease, neoplasm, and vasculitis were ruled out by anamnestic, clinical, biological and radiological data (Kwon et al., 2001). In the present case, the bone marrow aspiration was normal. A cerebral MRI revealed vascular lesions different from those of demyelinating diseases, multiple sclerosis or diffuse cerebrovascular atherosclerosis. According to the literature, abnormally high signal areas on T2-weighted images have been observed. Most lesions detected in MRI were infarctions in the border zone and the cortical areas with normal vasculature. Kono et al. (Kono and Itoh, 2009) suggest that Diffusion-weighted imaging should be carried out for patients with HES encephalopathy, even if the T2-weighted images are normal. A focal intracerebral hemorrhage was also reported in a few studies (Wang et al. 2012). Brain MRI showed similar findings in those with IHS and secondary hypereosinophilia such as infections, which suggests a leading role of eosinophils in central nerve system involvement in both primary and secondary hypereosinophilic syndrome (Lee et al., 2009).

Several pathogenetic mechanisms are discussed in

HIS-related encephalopathy (Lee et al., 2009; Wang et al. 2012). The lesions in the brain may result from direct invasion by eosinophils. Activated eosinophils induce injury in the human endothelial by releasing a number of cytopathic substances such as major basic protein. Encephalopathy has been reported to be caused by distant thromboembolic events secondary to IHS cardiopathy. Blood hyperviscosity with local thrombus formation could explain the border zone infarct. In our patient, the echocardiography was normal with the absence of atrial flutter/fibrillation and endocarditis. The brain lesions are probably caused by local toxicity of eosinophils.

In previous studies, high peripheral blood eosinophilia depends on clinical presentations (Kwon et al., 2001; Lee et al., 2009; Wang et al. 2012). An altered mental status is the most significant predictor of poor outcome but the early corticosteroids administration may be beneficial. For this reason, many authors suggest corticosteroids should be introduced as soon as possible without waiting for six months (Kono and Itoh, 2009; Kwon et al., 2001). Lee et al. (Lee and Ahn, 2014) report that Isolated CNS manifestations or corticosteroid treatment without intentional delay to fulfill the temporal criterion of HIS are associated with favorable outcomes. For this reason, in our patient, we did not respect the temporal window in the definition of HES in order to guarantee clinical improvement.

There are limited data in the previous studies concerning treatment (dose and duration) (Kono and Itoh, 2009 ; Kwon et al., 2001; Lee et al., 2009; Wang et al. 2012). The treatment consists of corticosteroids: oral prednisone or intravenous methylprednisolone followed by oral prednisone. It is reported that corticosteroids should be used for 1-2 years at a low dose (5–10 mg). Our patient has received this therapeutic regimen. At follow-up, after 1 year, there was no evidence of organ involvement including cerebral nerve system. Blood eosinophils were in the normal range.

The present case demonstrates that HIS-induced cerebral vascular lesions could be observed without

cardiopathy involvement. This case suggests that HIS should be considered when other causes of vascular lesions in cerebral MRI are ruled out. We highlight the necessity of introducing corticosteroids precociously in order to improve prognosis.

Disclosure of Interest

The authors declare that they have no conflicts of interest concerning this article.

CONCLUSION

HIS-related encephalopathy is a rare but potentially severe condition. Clinical futures were atypical and MRI findings could contribute to early diagnosis. Treatment should not be delayed as prognosis could be improved by early administration of corticosteroids.

REFERENCES

- Kono Y, Itoh Y (2009). Diffusion-weighted imaging of encephalopathy related to idiopathic hypereosinophilic syndrome. *Clin Neurol Neurosurg.*;111:551-3.
- Kwon SU, Kim JC, Kim JS (2001). Sequential magnetic resonance imaging findings in hypereosinophilia-induced encephalopathy. *J Neurol.* ; 248:279-84.
- Lee D, Ahn TB (2014). Central nervous system involvement of hypereosinophilic syndrome: a report of 10 cases and a literature review. *J Neurol Sci.*; 347: 281-7.
- Lee EJ, Lee YJ, Lee SR, Park DW, Kim HY (2009). Hypereosinophilia with multiple thromboembolic cerebral infarcts and focal intracerebral hemorrhage. *Korean J Radiol.* ; 10: 511-4.
- Wang L, Wei L, Wang JC, Liu YH, Deng YC (2012). Idiopathic hypereosinophilic syndrome revealed by encephalopathy. *J Clin Neurosci.*; 19:1746-8.