

*Original Research Article*

# Early and long term results of the treatment of vascular lesion of lip with diode laser 980 nm compared with conventional method

<sup>1</sup>Prof. Ass. Merita Bardhoshi, <sup>2</sup>Prof. Dr. Med Norbert Gutknecht DDS, Phd,  
<sup>3</sup>Prof. Ass Edit Xhajanka, <sup>4</sup>Dr. Neada Hysenaj and <sup>5</sup>Dr. Erda Qorri

**Abstract**

<sup>1</sup>Medicine University Department of Oral Surgery Dibra Street 63 Tirana Albania

<sup>2</sup>RWTH Aachen University Department of Restorative Dentistry, Pauwelsstr. 30 D-52074 Aachen

<sup>3</sup>Medicine University, Prosthetic Department, Dibra Street Tirana Albania

<sup>4</sup>Dental Clinic, Dibra Street Tirana Albania

<sup>5</sup>Albanian University

\*Corresponding Author's E-mail:  
Email: neadah@yahoo.com

Several laser systems have been developed using principles of selective photothermolysis. This study comprised 60 patients (32 males and 28 females) aged 10 to 80 years treated for vascular lesions of the lip. The research protocol was performed in two groups. In the first group, 30 patients were treated with 980 nm diode laser and the second group (the control group) 30 patients were treated with cold scalpel. For the laser group a 980 nm Diode laser was used. Laser energy was delivered through a fiber optic with gauge 300 micrometer and average power 3W in a continuous mode from 10 to 60 seconds according to the size of the lesion. The results were evaluated as early and long-term results. In contact and non-contact. From the control group 6 cases out of 30 (20% of the patients) reported functional disturbance. In all patients treated with 980 nm diode laser scar formation was not observed. Clinical applications of 980 nm diode laser for the management of vascular lesion of lip is of beneficial effects due to the good absorption in hemoglobin. Laser treatment versus scalpel surgery is minimal invasive and minimal aesthetic results.

**Keywords:** Benefits, Diode laser, Lip, Vascular lesion

## INTRODUCTION

Mulliken and Glowacki introduced a simple classification in 1982 that was based on the clinical, histochemical and cellular criteria to distinguish between the various vascular anomalies (Genovese et al., 2010). They described two distinct entities— hemangiomas and vascular malformations. Acquired lesions may be traumatic or idiopathic in origin. Haemangiomas present with variable morphology. Some are small and hardly noticeable, whereas others are large and disfiguring. Haemangiomas that are flat and appear reddish are considered superficial and those that are deep beneath the skin and appear bluish are called deep haemangiomas (Thurnherr and Tschopp, 2000). When a haemangioma is superficial and deep is called compound hemangioma. The correct

diagnosis is critical for proper treatment. Vascular malformations are always present at birth though some may not be apparent until a later stage and they never proliferate or involute. Instead they expand slowly and relentlessly throughout life, in pace with the growth of the patient. Trauma, puberty and pregnancy can cause accelerated growth. These lesions are sub-classified according to the predominant type of vessel and characteristic of flow like capillary malformation, venous malformation and arteriovenous malformation. They present initially as flat pink macules. They are usually soft, compressible and enlarge in size when venous pressure is increased. Some lesions such as venous lakes and varicosities are part of the normal aging process. The

congenital anomalies may be further subdivided according to vessel type. Capillary, venous and lymphomatous malformations are low-flow lesions, whereas arteriovenous lesions are high flow (Genovese et al., 2010; Ethunandan and Timothy, 2006; Romanos, 2012; Alling, 1999). Malformations may be seen in a number of different syndromes involving the oral cavity as well as the head and neck like: Rendu-Osler-Weber syndrome, Sturge – Weber syndrome, Maffucci´ syndrome (Romanos, 2012). Accurate terminology leads to precise identification of the vascular entity. In most cases an accurate history and physical examination will help establish the diagnosis (Van Doorne et al., 2002; Lapidoth et al., 2005; Ternowitz, **Provide year**; Alling, 1999). They can be situated in different areas of the oromaxillofacial region; tongue, lip, palate, buccal mucosa, gingiva (Romanos, 2012). Numerous methods of treatment have been used such as cryotherapy, embolization, sclerotisation, cold scalpel and combination of these. They are variable in their success and all can be complicated by scarring. The choice of treatment depends on the type of lesion (vascular content), location, depth and characteristics of flow of the lesion (Lapidoth et al., 2005; DeBiase et al., 2006; Genovese et al., 2010). Management of these lesions with laser is an option. Because of the esthetic importance of the lip, the discrete anatomic borders such as the vermilion border and their functional importance the use of lasers for treatment in this region has some important benefits (Romanos, 2012). Several laser systems have been developed using principles of selective photothermolysis (DeBiase et al., 2006). The target chromophore in vascular lesions is oxyhemoglobin present in the red blood corpuscles which circulates in blood vessels. Laser therapy is a good method to treat vascular lesions. Among different laser systems I choose the application of 980 nm diode laser for the management of vascular lesions of the lip due to the fact that the wavelength of 980 nm is good absorbed in hemoglobin and this characteristic makes it possible to achieve very good coagulation and hemostasis that is very important for vascular lesions.

## **PATIENTS AND METHODS.**

This study comprised 60 patients (32 males and 28 females) aged 10 to 80 years treated for vascular lesions of the lip. The research protocol was performed in two groups. In the first group 30 patients were treated with 980 nm diode laser and the second group, the control group 30 patients treated with cold scalpel. Treatment was conducted from May 2007 to May 2012 at the Department of Oral Surgery, Dental Clinic of the University of Tirana, Albania. All patients are provided with clinical files from the laser group 20 patients were medically free and 10 others compromised (diabetic 3, cardiopathy 3 and under anticoagulant therapy 4). From the control group 18 patients were medically free and 12 others compromised

(diabetic 4, cardiopathy 4, under coagulant therapy 4). For all patients, the lesions were considered to be vascular lesions based on their medical history, age, thorough extra and intra oral examination and findings of ultrasonography. All patients were given a written and verbal information on the nature of laser treatment and signed informed consent forms were obtained prior to treatment. The follow-up period was one month, six months, one year and three years for the evaluation of the characteristics of wound healing as early and long term results. All stages of treatment and follow-up are photographically documented serving for comparative long-term evaluation.

## **Method**

Treatment was performed on an outpatient basis under local anesthesia. For the laser group a 980 nm Diode laser was used. Laser energy was delivered through a fiber optic with gauge 300 micrometer and average power 3 W in a continuous mode from 10 to 60 seconds according to the size of the lesion in contact and non-contact. The laser tip was placed non-contact mode 2 mm away from the area. It started by working around the border of each lesion circling around it several times all in one direction, changes of color, visible shrinkage were used as signal for the end point of treatment, until blanching of the treated area and photocoagulation was completed. In contact mode, the fiber was in contact with mucosal surface of the lesion using gentle pressure, it was advanced into the substance of vascular lesion to the periphery four such passes are required. The treated surgical area was bloodless and intralesional photocoagulation was completed. The treated areas were iced for 3 to 5 minutes. After treatment analgesic medication was prescribed to be used if necessary but no antibiotics were prescribed. Instructions for post-surgical behavior treatment consisting in ice compress for 2 hours, abstention of warm food and drinks intake, to place Vit E ointment on the laser area and to avoid sun exposure for one month. The patients of control group were treated with conventional removal techniques by means of blade. Excision as surgical technique was performed to fully enucleate the lesion and the wounds were sutured. Antibiotics were prescribed for all patients and for the patients under anticoagulant therapy had interrupted it prior to surgery. The follow-up visits for the protocol research for laser group and control group were scheduled 10 days, one month, six months, one year and three years. Pain, bleeding, swelling, scar formation, functional disturbance, aesthetic result, recurrence as well as wound healing characteristics were evaluated.

## **RESULTS**

In this study, according to the protocol research the results

from two groups of populations were compared. The first is a group of 30 patients treated with 980 nm diode laser (Sirona laser) with different vascular lesion of the lip. A second group considered as the control group was treated as control group was treated by conventional surgical blade manner. The results were evaluated as early and long-term results. The patients of laser group were treated in one session. In this study is included a case of vascular of entire lower lip which was treated in five sessions, in different section. Another case to be consider from laser group is a patient with vascular lesion in lower and upper lip which was treated in different session in distance of 2-3 weeks from each other. Time of surgery for laser group was very short that make possible a surgical comfort of the patient the and no sutures were required and the wound was healed in two or three weeks depending of the size of the lesion. None of the patients reported complications during wound healing here included compromised patients. On the basis of the data reported from the patients of control group 3 to 30 patients showed delays time due to local problems favored from compromised patients. The parameters evaluated are the following:

### **Bleeding**

The bleeding during the surgical removal of vascular lesions can be considered a typical feature of such treatments. During the treatment with laser no bleeding in all patients was observed (Figure 1.b, 2.b). After the excision with scalpel from the control needed prolonged packing and sutures were used to close surgical wound.

### **Pain**

The second parameter evaluated was post-surgery pain. Only one patient out of 30 treated with laser reported pain when the effect of local anesthesia stopped. The other patients had an optimal post-surgical comfort and they didn't refer pain. Among the patients treated with conventional blade surgery 22 out of 30(70 % of the patients) referred pain solved by analgesic drugs for some days.

### **Swelling**

Another parameter evaluated in the control visits during follow-up during first week after treatment was swelling. None of the patients treated with laser reported swelling. On the other hand, 20 patients out of 30(66% of the patients) from the control group referred swelling the first week after the surgical excision.

### **Scarring**

A common problem related to the lesions of the lip was scar formation. Scar formation was evaluated at the control visit one month after the treatment. In all patients treated with 980 nm diode laser scar formation was not observed. (Figure 1c, 2.c). On the other hand, in all patients treated with conventional blade surgery scar formation were observed in the site of the performed excision.

### **Functional disturbance**

The parameter functional disturbance was evaluated six months after the treatment. No functional disturbance was recorded and the lip looked normal in colour and consistence from the laser group. From the control group 6 cases out of 30(20% of the patients) reported functional disturbance

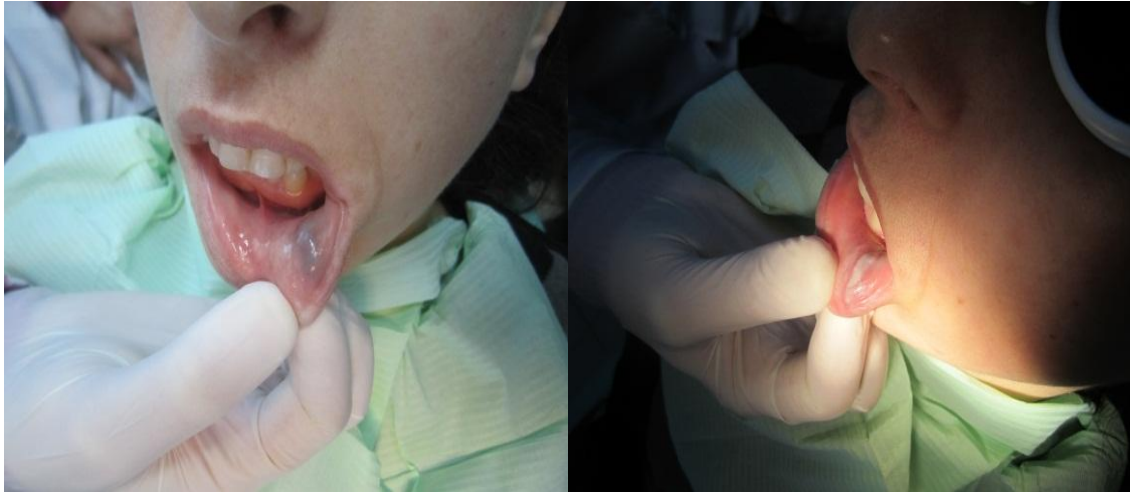
### **Recurrence**

Recurrence was evaluated as long term result at the follow-up of one year, two years and three years after the treatment. According the clinical data reported by patients treated with laser no recurrences were observed. Only one case from the control group was reported recurrence of the lesion during the first year after the excision. (Insert figures)

### **Statistical Analysis**

All statistical test and graphics were created using SPSS for Medical Calculation MedCalc. Data were expressed as mean  $\pm$  standard deviation and 95% confidence interval and the statistical significance was estimated by Student's *t*-test and *p* values  $<0.05$  were considered significant. From May 2007 to May 2012 we treated 60 patients:32 males and 28 females mean age  $45\pm 2$  years.

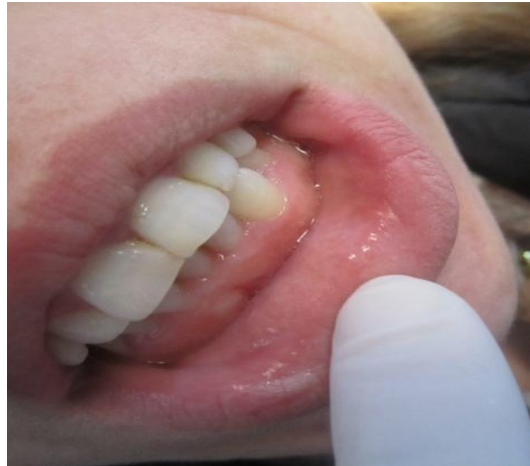In this investigation, it is used the Cochran's Q Test, which is a non-parametric statistical test to verify if scalpel and laser treatments have identical effects or not This analysis is a two-way randomized block designs where the response variable is coded as two possible outcomes; coded as 0 and 1. (Woldrige, 2003). Moreover, this test relies on the null hypothesis where states that both treatment have identical effect and from the other hand the alternative one states that there is a difference on the effectiveness among treatments. These tests were performed for every variable we selected such as: pain, bleeding, edema swelling, functional disturbance, scar formation and aesthetic result. Accordingly, the null hypothesis for the Cochran's Q test is that there are no differences between the variables; the equivalence of the



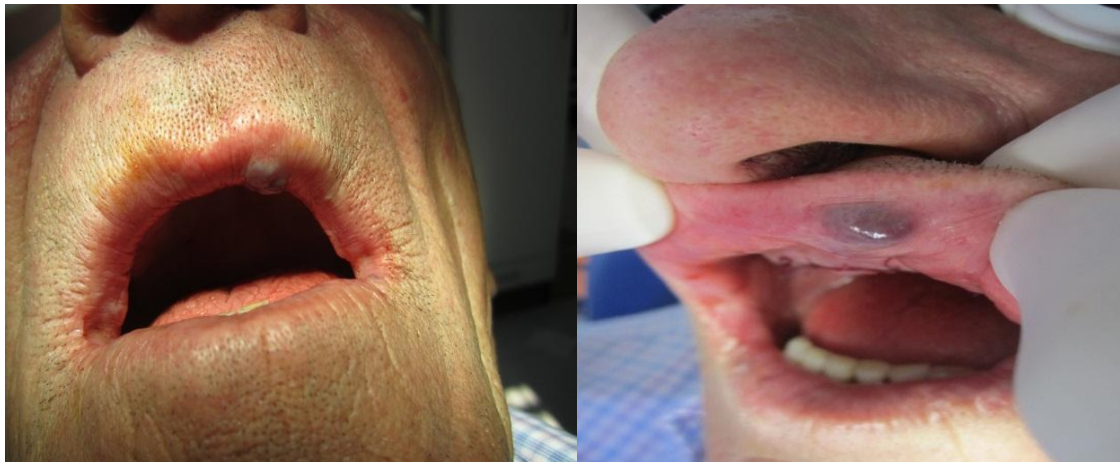
**1.a** Vascular lesion of lip

**b.** Immediately after the treatment

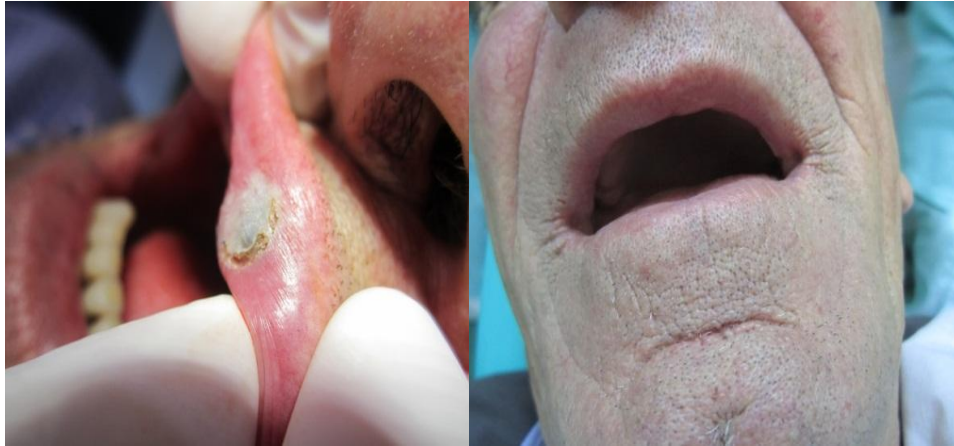**Figure 1.** Photocoagulation was completed. Surgical field was bloodless



**Figure 1c.** 4 weeks after the treatment with 980 diode laser wound was completely healed without scarring



**Figure 2a.** Vascular lesion



**Figure 2b.** Immediately after the treatment **c.** 4 weeks after the treatment

groups under control. If the calculated probability is lower than 0.05 (in this case 0.001) the null-hypothesis is rejected and variables are significantly different from each other. This suggests that there is statistically a difference between the groups which were applied the laser and the control group; the scalpel method.

## DISCUSSION

Many vascular lesions involve the lip. Different methods can be used to manage these lesions with beneficial effect. It is important to well determine the advantages and disadvantages of each modalities of treatment and the surgeon may choose any method of management. The surgical excision is a treatment option. The goal of each surgical procedure is to remove a pathological lesion avoiding tissue damages and allowing the healing without complications in short or long time (Erika et al., 2010). Total resection of these lesions has the risk of hemorrhage. Operative bleeding was evident in the clinical cases included in this study treated with scalpel. To prevent this complication preoperative embolization or sclerotherapy can be performed [26]. As it is reported in literature sclerotherapy is a modality of treatment (Yang et al., 2009; Mariano et al., 2011), but it is a good choice if it is associated with surgery (Erika et al., 2010; Jeddy et al., 2012; Kono et al., 2006; Yang et al., 2009; Johann et al., 2005; Mariano et al., 2011; Levy and Berwald, 2004). Another point to be considered regarding surgical resection is the aesthetic result. My results and the reports of authors (Erika et al., 2010; Jeddy et al., 2012; Kono et al., 2006) had proved that surgical excision produce scarring and for aesthetic reasons another plastic surgical intervention is needed. Aesthetic result is the disadvantages of this method of treatment (Zhou et al., 2005). In the mouth, mainly on the lip there is an aesthetic challenge when surgery or sclerotised agent are used particularly in large lesions and in hemangiomas Azevedo

et al. (2009).

Electrocautery which also acts by means of coagulation may cause scarring particularly on the lip border Azevedo et al. (2009). The use of cryosurgery may result in aesthetic scarring mainly in the lesion located on the vermillion border of the lip Azevedo et al. (2009). Different laser systems are used for the treatment of these lesions according the publications (Johann et al., 2005; Berlien et al., 1993; Thurnherr and Tschopp, 2000; White et al., 1998; Glenn, 2010; Caprioglio et al., 2011). Diode laser photocoagulation technique was effective in the treatment of vascular lesion required only one irradiation Azevedo et al. (2009). Azevedo et al. (2009) reported that 810 nm diode laser was successfully used for the management of vascular lesion with good postoperative results Azevedo et al. (2009). Genovese et al. (2010) reported that the use of the use of 980 nm diode laser in the treatment of vascular lesion reduces bleeding during surgery with a consequent reduction in operating time and provides hemostasis. Romanos and Nentwing1999 confirmed that with 980 nm diode laser the coagulation of the tissue was excellent. Laser procedure is well accepted by all patients included in this study as it is showed in different publications (Bogdan et al., 2010; Lawrence, Provide year; Johann et al., 2005; Mariano et al., 2011; Berlien et al., 1993; Thurnherr and Tschopp, 2000; White et al., 1998; Glenn, 2010; Romanos, 2012; Alling, 1999; Walker and Volland, 2009; Bardhoshi, 2012; Saafan and Tarak, 2012; Luciane et al., 2010; Azevedo et al., 2009).

In this study, different age groups were treated from 10 to 80 years old. Short time of laser surgery is a huge advantage for pediatric and geriatric patients who tolerate with difficulty the surgical intervention. Children are afraid and anxious from the dental chair (Lawrence, Provide year) and the generation of old people are health compromised and cannot tolerate long surgical procedure. Some of the patients from laser group were under anticoagulant therapy and it was not necessary to interrupt it before the treatment (INR>1,7) versus the patients of

control group it was mandatory to interrupt the administration of anticoagulant drugs before intervention according to the treatments' protocol. No complications were observed during the wound healing time, here included the compromised patients. This is the same results comparing the report of authors from literature (Bogdan et al., 2010; Genovese et al., 2010; Moghtader, 2012; Alling, 1999). Bogdan et al., 2010; Desiate et al., 2009; Romanos and Nentwig, 1999 reported in the publications good results after the treatment of vascular lesions with 980 nm diode laser. At the 4-weeks follow-up they referred that all vascular lesions had healed without leaving any macroscopically visible scars. Results of this study in comparison with the results of referred authors showed that 980 nm diode laser allows treatment of vascular lesion of lip in a simple, fast and safe manner with minimizing the danger of massive haemorrhage and huge lip structure loss. The approach is simple and with satisfactory results.

## CONCLUSION

Clinical applications of 980 nm diode laser for the management of vascular lesion of lip is of beneficial effects due to the good absorption in hemoglobin. Laser treatment versus scalpel surgery is minimal invasive and minimal aesthetic results. Postoperative period is comfortable for the patients treated with 980 nm diode laser regarding to the post-operative pain and swelling compared with the patients treated by conventional method. The patients under anticoagulant therapy were treated without substitution prior to laser surgery and there was not bleeding during the treatment Laser treatment is short in time and well-accepted by all age group. Surgical lased wounds were healed in time, without scar formation and functional disturbance

## REFERENCES

- Alling C (1999). Laser Applications in Oral and Maxillofacial Surgery Textbook Chapter 9 pp 167-181
- Bach G (2009). Diode laser assisted combination therapy of a lip hemangioma Laser International Journal of laser in dentistry N. 3 pp 41-46
- Bardhoshi M (2012). The management of pyogenic granuloma with diode laser 980 nm Laser international magazine of laser in dentistry Vol 4 Issue 1 / pp 26-27
- Bardhoshi M (2011). The treatment of prominent frenulum with diode laser 940 nm " Laser international magazine of laser in dentistry Vol.3 Issue 1/ pp18-19
- Bardhoshi M (2011). Treatment of epulis using the 980 nm diode laser Laser international magazine of laser in dentistry Vol.3 Issue 3 / pp 16-17
- Barry Z, Stile F (2002). Vascular lip enlargement Haemangiomas - Tenets of therapy British Journal Oral Maxillofacial surgery December ; 40 pp 497-503
- Berlien HP , Philipp C, Enge –Murke and al (1993). Use of laser in vascular surgery ZentrabChir ; 118 ( 7 ) : 383-9
- Bogdan V. Crisan, MihaelaBacicut, GrigoreBacicut, Radu S (2010). CampianLaser Treatment in Oral and Maxillofacial Hemangioma and Vascular Malformations 34 Timisoara Medical J., Vol. 60, No. 1
- Borchers R (2008). Comparison of Diode lasers in soft tissue surgery using cw and superpulsed mode Master Thesis RWTH University Aachen
- Bu J, Shi Hand al (2004). Oral venous lakes : Aclinicopathologic analysis of 20 cases Lasers Surgery Medicine; 34 (2) : 189 - 192
- Caprioglio C, Olivi G , Genovese M (2011). Paediatric laser-assisted dentistry LASER International Magazine of laser in dentistry N.1 pp 22- 23
- DeBiase M, Ruffon D, Pellegrini M, Bruzzeri G, Pugliese B, Spadari F (2006). Therapie laser-assistited eitessutimolliorali Rivistaitaliana di Stomatologia;4: 16-20
- Desiate A, Stefenia C, Tullo D , Profeta G, Bellini A (2009). 980 nm diode laser in oral and facial practice: current state of the science and art Int J Med Sci; 6 : 358-364
- Erika D, Rafael S, and al (2010). Lip cavernous Hemangioma in a Young Child Brazilian Dental Journal vol.21 n.4 .
- Ethunandan M, Timothy K Mellor (2006). Haemangiomas and vascular malformations of the maxillofacial region – A review British Journal of Oral and maxillofacial Surgery ;44 : 263-272
- Genovese WJ, Santos MT, Fallopa F, Souza Merli LA (2010). The use of surgical diode laser in oral haemangioma: a case report PhotomedicineLaser Surgery Feb 28; 1 : 147-51
- Glenn A (2010). The diode laser as an electrosurgery replacement Laser feature June pp 56-64
- Hartman E.H.M, Spouwen P.H.M , Rieu P.N.M.A (Provide year). Surgical treatment of haemangiomas and vascular malformations in functional area Pediatric Surgery International Vol.11 Number 56 : 308-311
- Jeddy N, Duraijan J, and al (2012). A giant compound hemangioma of lower lip J Oral Pathology SepDec ; 16 (3 ) : 438 - 440
- Johann AC, Aguiar MC, Gomez RS and al (2005). Sclerotherapy of benign oral vascular lesion with ethanoamineoleate : an open clinical trial with 30 lesions Oral Surgery Oral Medicine Oral Pathology Nov ; 100 (5) : 579-84
- Kono T, Sakurai H, Groff WF and al (2006). Comparison study of a traditional pulsed dye laser versus a long pulsed dye laser in the treatment of early childhood Lasers surgical Medicine Feb;38(2): 112 - 115
- Kuo HW, Yang CH (2003). Venous lake of the lip treated with a sclerosing agent : report of two cases Dermatology Surgery Apr; 29 (4) : 425 - 428
- Lahey E III, Kaban L (Provide year). Evolution and management of Maxillofacial Vascular lesions Textbook Chapter 111
- Lapidoth M, Amital D ,Yaniv E (2005). Treatment of facial venous malformations with combined Radiofrequency current and 900 nm diode Dermatology Surgery; 31: 1308-1312
- Lawrence Kotlow (Provide year). Lasers and soft tissue treatments for pediatric dental patients Alpha Omegan Vol.101 Number 3: 140-151
- Levy JL, Berwald C (2004). Treatment of vascular abnormalities with a long pulse diode at 980 nm Journal Cosmetic laser therapy Dec ; 6 (4) : 217 - 221
- Lopez Gutierrez JC, Lopez S (1997). Diode laser in the treatment of congenital venous malformations Plastic and Riconstructive Surgery Vol 100 December pp 1664-1673
- Luciane H. Azevedo, Vivian C. Galletta, Carlos de Paula Eduardo and Dante A. Migliari (2010). Venous Lake of the Lips Treated Using Photocoagulation with High-Intensity Diode Laser Photomedicine Laser Surgery April ; 28 ( 2 ) : 263-265
- Maghan E Stier, Sharon A Glock, Ronella I (2008). Hirsch Laser treatment of pediatric vascular lesions : Port wine stains and hemangiomas Journal Am AcadDermatolog; 58: 261-85
- Mariano FV , Vargas PA , Della Coetta R (2011). Sclerotherapy followed by surgery for the treatment of oral hemangioma : a report of two cases Gen Dent May-Jun ; 59 (3) pp 121-125
- Mitchel P (Provide year). Goldman Cutaneous and Cosmetic Laser surgery Chapter 2: 31-93
- Moghtader D (2012). Wiedurcheine Lasertherapieeinejunge Frau wieder "kissable" wurde Laser Journal Number 4 pp 10- 12
- Niamtu J (2004). The treatment of vascular and pigmented lesions in oral and maxillofacial surgery Oral Maxillofacial Surgery Clinics of North America;16 pp 239-254
- Romanos G (2012). Lasereinsatz in der Chirurgie Jahr Buchlaser-zahnmedizin pp 40-43

- Romanos G, Nentwig G (1999). Diode laser 980 nm in Oral and maxillofacial surgical procedures : Clinical Observations based on clinical applications *Journal of Clinical Laser Medicine & Surgery* Volume 17, Nov pp . 193-197
- Saafan A, Tarak J (2012). Treatment of low-flow tongue lesions by diode lasers intralesional photocoagulation *Journal of American Science* ; 8 ( 6 ) pp 247-251
- Salins P, Kumar S and al (2005). Management of large vascular lesion of lip A case report *Oral Surgery, Oral Medicine , Oral Pathoogy* Vol.100 Issue 5 Nov pp 579-584
- Ternowitz Th (Provide year). Vascular and benign pigmented lesions Website of Stravanger University Hospital
- Thurnherr S, Tschopp K (2000). Experiences with the treatment of vascular malformations using the Nd: YAG laser *Schweiz Med Wochenschr .;Suppl* 125 : 106 S-108 S
- Turabian Kate L (2007). A manual for writers of research Papers, Theses, Dissertations 7 th Edition
- Van Doorne L, M. De Maeseneer, C. Stricker, R. Vanrensbergen, M (2002). Stricker Haemangiomas and vascular malformations of the maxillofacial region *British Journal of Oral and Maxillofacial Surgery* 40: 497–500
- Vasquez D , Vicente FJ (1998). Treatment of oral vascular anomalies by transfixion technique *Dermatology Surgery*; 24 (10) : 1087 - 1091
- Walker R, Volland G (2009). Advanced Dental laser Surgery *LASER International magazine of laser in dentistry* N.1 pp 32-33
- White JM , Chaudhry SI, Kudler JJ and al (1998). Nd: YAG and CO2 laser therapy of oral mucosal lesions *J Clin Laser Med Surg* Dec ; 16 ( 6 ): 229-304
- Yang HY, Zheng HJ, and al (2009). Long pulsed Nd:YAG laser treatment in vascular lesions of oral cavity *Journal Craniofacial Surgery* Jul ; 20 (4) : 1214 1217
- Zhou GY, Zhang ZY , Zhang CP and al (2005). Clinical study on laser therapy of the venous malformations and hemangioma in oral and maxillofacial regions *Zhonghua Kou Yi XueZaZhi* May ; 40 (3) : 200-2
- Zide B, Paul M , Frank L (2007). Treatment of vascular lesion of lip *Medical Bulletin* VOL. 12 No. 11 November