

Original Research Article

# Effects of Methanolic Extract of the Rind of *Citrullus Lanatus* (Watermelon) in Aspirin Induced Gastric Ulceration in Male Wistar Rats

T.A. Kolawole<sup>1\*</sup>, D.V. Dapper<sup>2</sup>, O.B. Oluwatayo<sup>1</sup> and C.Wali<sup>3</sup>

Abstract

<sup>1</sup>Department of Physiology, Madonna University Elele Campus, Rivers State, Nigeria

<sup>2</sup>Hemorheology and Immunology Research Unit, Department of Human Physiology, College of Health Sciences, University of Port Harcourt, P.M.B. 5323, Port Harcourt, Nigeria

<sup>3</sup>Anatomy Department, Madonna University Elele Campus, Rivers State.

\*Corresponding Author's Email: [tolueneok02@yahoo.com](mailto:tolueneok02@yahoo.com)

The use of medicinal plants in diseases is as old as man. The World Health Organization (WHO) has long recognized and drawn the attention of many countries to the ever increasing interest of the public in the use of medicinal plants and their products in the treatment of various ailments. Peptic ulcer is a common global health problem with increasing incidence and prevalence. Plant based medicines are now considered as an alternative approach to control. The present research was carried out to investigate the extract of the rind of *Citrullus lanatus* for ameliorative effects in aspirin induced gastric ulceration in rats. Thirty (30) male rats weighing between 180g and 250g were used for this study. The rats were randomly divided into five groups: Groups 1 to 5. Gastric ulceration was induced in all the rats by using 0.2gm/kg of aspirin orally. The rats were subsequently treated as follows: Group 1 served as the control (received 2ml/kg bw of vehicle), Groups 2, 3 and 4 received 100mg/kg, 200mg/kg and 500mg/kg bw of the methanolic extract of the rind of *Citrullus lanatus* respectively, while Group 5 received 200mg/kg bw of Cimetidine. Treatment was done for 21 days. On day 22, gastric juice volume, gastric acidity, ulcer index, gastric pH and percentage ulcer inhibitions were determined. Results obtained showed that, compared to control rats, administration of the methanolic extract of the rind of *Citrullus lanatus* protected the gastric mucosa against aspirin effect by significantly reducing the gastric juice volume, gastric acidity, and ulcer index ( $p < 0.05$ ) in a dose dependent manner while the gastric pH ( $p < 0.05$ ) and the percentage ulcer inhibition were significantly increased ( $p < 0.05$ ) in rats treated with the extract when compared with the control and the effect is similar to that of rats treated with Cimetidine. Activities of Super oxide dismutase (SOD) and Catalase were significantly increased ( $p < 0.05$ ) while Malondialdehyde (MDA) was significantly decreased ( $p < 0.05$ ) in high extract dose treated rats when compared with the control. This study shows that the extract possess curative effect against aspirin induced gastric ulceration in male wistar rats. The findings suggest that the methanolic extract of the rind of *Citrullus lanatus* exerts a possible beneficial ameliorative effect on the stomach of the male albino wistar rats exposed to aspirin ulceration.

**Keywords:** Ameliorative effect, Aspirin, *Citrullus lanatus* rind, Gastric ulceration, Rats

## INTRODUCTION

The use of medicinal plants in curing diseases is as old as man (Grabley and Thierickee, 1999; Akuodor *et al.*,

2010). The World Health Organization (WHO) has long recognized and drawn the attention of many

countries to the ever increasing interest of the public in the use of medicinal plants and their products in the treatment of various ailments. These plants which are found in our environment enjoy wide acceptability by the population and serve as cheaper alternatives to orthodox medicine (Sofowora, 1993; Akah and Nwabe, 1994). One of such plants is watermelon. Watermelon (*Citrullus lanatus*, family *Cucurbitaceae*) fruit has deep green or yellow colored smooth thick exterior rind with gray or light green vertical stripes. Inside the fruit is pink, red or even yellow in color with small black seeds embedded in the middle third of the flesh. Generally, watermelon flesh is the main consumable portion; however, the outer rind is also used in some parts of the world (Touhami *et al.*, 2007; Levi *et al.*, 2001). The fruits of cucurbits are very useful in terms of human health, e.g purification of blood, constipation, good for digestion, and energy. (Sentu and Debjani, 2008). The anti-ulcer potential of the *cucurbita pepo* fruit pulp has also been reported earlier (Miller, 1987). The rinds can be fermented, blended and consumed as juice, stir fried, stewed or more often pickled. Pickled *Citrullus lanatus* rind is also commonly consumed in the southern United States (Mandel *et al.*, 2005). The rind has also been shown to contain mainly citrulline which is a known stimulator of nitric oxide (Rimando and Perkins-Veazie, 2005). Watermelon is indeed a source of known and characterized antioxidant molecules, such as carotenoids (lycopene and B-carotene), amino acids like citrulline (Rimando and Perkins, 2005), minerals like potassium (Perkins and Collins, 2006), and superoxide dismutase (Bueno and Gimeenez, 1995). The rind has been shown to contain alkaloids, saponin, cardiac glycosides, flavonoids, phenol, moisture, lipid, protein, fiber and carbohydrates (Ercal *et al.*, 2001) also, its ameliorative effects on lead acetate induced toxicity on semen parameters and reproductive hormones of male albino wistar rats has been reported (Kolawole *et al.*, 2014). Gastric ulcer is produced by the imbalance between gastroduodenal mucosal protective defense mechanism and damaging force. Impaired mucosal defense is initiated in ulcer patients with normal levels of gastric acid and pepsin (Eamlamnam *et al.*, 2006). Therefore, prophylactic treatment to prevent gastrointestinal complications may be necessary in a substantial proportion of NSAID users. It is highly recommended in groups that are associated with a high risk of developing these complications (Naesdal and Brown, 2006). One of such NSAIDs is aspirin. Aspirin is a potent non-steroidal anti-inflammatory drug (NSAID) that is used for the treatment of rheumatoid arthritis and related diseases as well as the prevention of cardiovascular thrombotic diseases (Laine *et al.*, 2008). Gastric ulcer associated with the use of aspirin is a major problem. Many factors such as gastric acid and pepsin secretion, gastric microcirculation, prostaglandin E2 (PGE2) content (Laine *et al.*, 2008), proinflammatory cytokines interleukin (IL-1 $\beta$ ) and tumor necrosis factor

(TNF)- $\alpha$  (Santucci *et al.*, 1995; Appleyard *et al.*, 1996) play important role in the genesis of gastric mucosal damage, and its subsequent development.

The present study was undertaken to determine the possible role of the rind of *Citrullus lanatus* extract in Aspirin (NSAID) induced gastric ulceration in male wistar rats.

## MATERIALS AND METHODS

### Plant material and preparation of extracts

Fresh plants and fruits of watermelon were obtained from a local market in Rivers State, Nigeria. The plant materials were taxonomically identified and authenticated by Dr. Ekeke Chimezie of the Department of Plant Science and Biotechnology University of Port Harcourt. The plant was given a Herbarium number UPH/V/1,214.

The rinds were peeled off from the whole fruit washed thoroughly, sun-dried and milled into a fine powder. The method of extraction employed is percolation (Adesanya *et al.*, 2011). 24g of the powdered sample was soaked in a beaker containing 100ml of 98% methanol for a period of 48 hours and then filtered with a Whatman No. 1 filter paper size. The volume of filtrate obtained was 150ml before concentration; the filtrate was subsequently concentrated using a rotary evaporator. The weight of residue obtained was 8.5g.

### Determination of Median Lethal Dose (LD<sub>50</sub>)

Acute toxicity study (LD<sub>50</sub>) was determined using the method described by Lorke 1983. The (LD<sub>50</sub>) of the extract was found to be greater than 2000mg/kg body weight.

### Experimental design

Thirty male albino wistar rats were used for this study. The rats were aged 8 to 10 weeks and weighed between 170g and 200g. They were divided into five groups: Groups 1 to 5 of 5 rats each. Rats in each group were numbered 1 to 5 and placed in separate cages in the Animal House of Madonna University, Nigeria under natural day and night cycles. The rats had free access to normal rat chow and tap water *ad libitum*. They were allowed two weeks of acclimatization to their environment. After acclimatization, gastric ulcer was induced in all the rats by using 0.2gm/kg (Mulazim *et al.*, 2011) of aspirin orally and subsequently treated as follows:

Group 1: Control Group; rats in this group were given 2ml/kg body weight of extract vehicle.

Group 2: Low Dose Extract Group; rats in this group were

treated with 100mg/kg body weight of the extract of the rind of *Citrullus lanatus*.

Group 3: Medium Dose Extract Group; rats in this group were treated with 200mg/kg body weight of the extract of the rind of *Citrullus lanatus*.

Group 4: High Dose Extract Group; rats in this group were treated with 500mg/kg body weight of the extract of the rind of *Citrullus lanatus*.

Group 5: Positive Control Group; rats in this group were given 200mg/kg body weight of Cimetidine.

The extract of the rind of *Citrullus lanatus*, Cimetidine and extract vehicles were administered to the rats daily using an oral cannula. All the rats were treated for a total of 21 days.

### Induction of gastric ulceration

After the last day of acclimatization, all the rats were fasted for 24 h with free access to water. Gastric ulceration was induced with oral administration of 0.2gm/kg body weight of Aspirin.

### Determination of gastric juice volume, gastric acid secretion and ulcer index

This was performed as earlier described by Heeba *et al.*, 2009. Four hours after the induction of gastric ulcer, the rats were killed by cervical dislocation, the abdomen was opened to remove the stomach and gastric contents were collected to determine the gastric juice volume. Five milliliters of distilled water was added to the gastric juice and the resultant solution was centrifuged at 3,000 rpm for 10 minutes. Gastric acidity in mEq/L was determined in the supernatant volume by titration to pH 7 with 0.0025 N of sodium hydroxide.

After removal of gastric content from the stomach, the stomach was pinned onto a soft board. Scoring of ulcer was subsequently done as follows: 1 = erosions of 1mm or less in diameter; 2 = erosions of between 1 to 2mm in diameter; 3 = erosions greater than 2mm in diameter. The overall scores were divided by a factor of 10 and the result obtained designated as the ulcer index (Main and Whittle, 1975). The percentage of ulcer inhibition was also calculated as follows:

$$\text{Percent ulcer inhibition} = \frac{\text{Mean ulcer index of control} - \text{Mean Ulcer index of test}}{\text{Mean ulcer index of control}} \times 100$$

### Measurement of pH

The hydrogen ion concentrations of samples of gastric contents for each rat were determined using a pre-calibrated Beckman pH meter.

### Superoxide dismutase (SOD) activity

The levels of SOD activity was determined by the method of Misra and Fridovich (1972). This involves inhibition of epinephrine autoxidation, in an alkaline medium at 480nm in a UV vial spectrophotometer. For the determination of specific activity of SOD in homogenate sample of gastric tissue, the rate of autoxidation of epinephrine was noted at 30 seconds intervals in all groups. The enzyme activity was expressed in arbitrary units considering inhibition of autoxidation, as 1 unit of SOD specific activity.

### Malondialdehyde assay-Lipid peroxidation

Lipid peroxidation was estimated in terms of thiobarbituric acid (TBA), using Malondialdehyde (MDA) concentration. Two ml of TBA reagent and 1ml of trichloroacetic acid (TCA) were mixed with 2ml of homogenate of gastric tissue. The mixture was heated at 60°C for 20 minutes. It was then cooled and centrifuged at 400rpm for 10 minutes. The absorbance of the supernatant was read at a wavelength 540nm.

### Statistical analysis

The results of this study were expressed as mean and standard error of mean (Mean  $\pm$  SEM). Statistical significant between the groups was assessed using the one way analysis of variance (ANOVA). A p value less than 0.05 was considered statistically significant. Results are as presented in tables, and photomicrographs.

## RESULTS

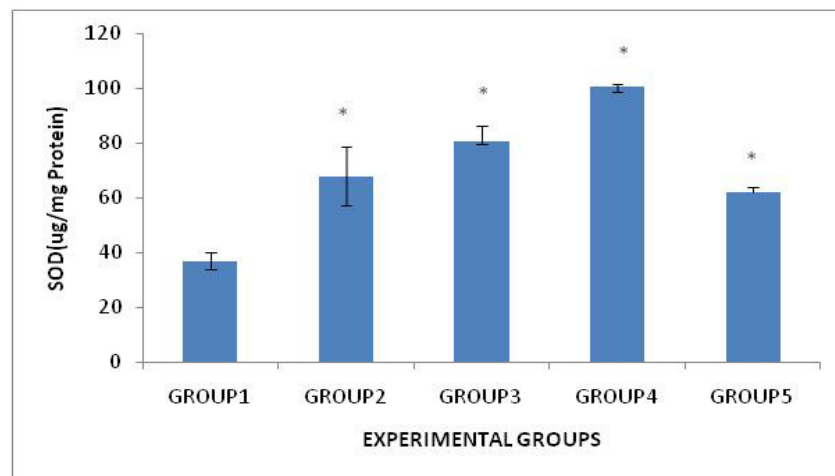
Effects of the extract of *Citrullus lanatus* on gastric juice volume, gastric acidity, ulcer index and percentage ulcer inhibition.

Table 1 shows the effects of the extract of the rind of *Citrullus lanatus* on gastric juice volume, gastric acidity, mean ulcer index and percentage ulcer inhibition in male albino wistar rats in the present study. At doses of 100, 200 and 500 mg/kg body weight the extract significantly reduced gastric juice volume in a dose dependent manner ( $p < 0.05$ ); compared to rats in the control group (Group 1). This effect is similar to that of the administration of Cimetidine at a dose of 200mg/kg body weight seen in rats in Group 5. The extract significantly reduced the acidity of the gastric juice in Group 4 rats ( $p < 0.05$ ); an effect comparable to that of Cimetidine at a dose of 200mg/kg body weight. Furthermore, at all doses administered, the extract significantly reduced the mean ulcer index in a dose dependent manner ( $p < 0.05$ ) compared to rats in the

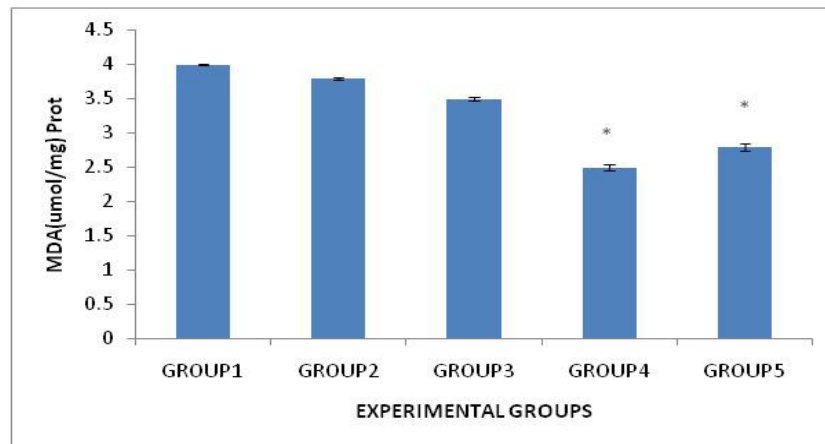
**Table 1.** Effects of the extract of *Citrullus lanatus* on gastric juice volume, gastric acidity, ulcer index, percentage ulcer inhibition and gastric pH.

Groups	Gastric Volume (ml/4h)	Gastric Acidity (mEq/l)	Ulcer Scores	% Inhibition	Gastric pH
Group1 Control	6.14 ± 0.05	0.40 ± 0.00	1.76 ± 0.17	-	4.68±0.12
Group 2 (100mg/kg) extract	5.80 ± 0.00*	0.40 ± 0.01	1.16 ± 0.18*	34.1*	5.40±0.11*
Group 3 (200mg/kg) extract	5.30 ± 0.18*	0.40 ± 0.01	0.88 ± 0.11*	50.0*	5.89±0.14*
Group 4 (500mg/kg) extract	5.16 ± 0.04*	0.29 ± 0.03*	0.50 ± 0.07*	71.6*	4.95±0.17*
Group 5 (200mg/kg) Cimetidine	5.18 ± 0.03*	0.31 0.01*	0.87 0.19*	50.6*	6.00 0.19*

Data are represented as Mean±S.E.M. Statistical analysis was done by one-way ANOVA . \* Significant with respect to the control (p < 0.05) (n = 5 in each group).



(a)



(b)

**Figure 1.** Show the effects of methanolic extract of the rind of *Citrullus lanatus* extract on superoxide dismutase (SOD) (a) and Malondialdehyde (MDA) (b) activities in rats. MDA was measured in  $\mu\text{mol/mg Protein} \times 10^{-5}$

control group (Group 1); this effect is also similar to that of administration of Cimetidine at a dose of 200mg/kg

body weight seen in rats in Group 5. At all doses, administration of the extract caused a significant increase

in percentage ulcer inhibition in a dose dependent manner ( $p < 0.05$ ); similar to the effect of Cimetidine and comparable to rats in the control group (Group 1). Treatment with the extract caused a significant increase in gastric pH amongst rats in Groups 2, 3 and 4 compared to rats in both the control group (Group 1) and the Cimetidine group (Group 5).

### Effects on antioxidant enzymes

As shown in Figure 1a and b, there was a significant increase in SOD activities in extract groups (Groups 2, 3 and 4) and Cimetidine group (Group 5) rats when compared with control group (Group 1). Also, *the extract significantly* reduced ( $p < 0.05$ ) MDA concentration in the high extract dose treated groups (Group 4) when compared with control group (Group 1).

### DISCUSSION

The curative potential of the hydromethanolic extract of the rind of *Citrullus lanatus* against Aspirin-induced gastric ulceration was established in this study. The acetylsalicylic acid model has already been utilized for screening new compounds for their anti-ulcer effects. Use of this model for the same purpose has been employed by several workers including Akhtar and Munir (1989); Mulazim *et al.* (2011).

The extract exhibited an healing effect on the stomach against aspirin induced damage in a dose dependent manner and its effect was more pronounced in rats treated with the extract (Groups 2,3 and 4) than in the Cimetidine group (Group 5), a known cytoprotective agent.

In the present study, there was a significant increase in volume of gastric juice, acid output, and decrease gastric pH by aspirin. This result is in line with past research where aspirin has been reported to decrease gastric juice pH and increase the volume of gastric juice (Wang *et al.*, 2007), and increase acid output (Jainu *et al.*, 2006).

Nonsteroidal anti-inflammatory drugs (NSAIDs) induce gastric damage ranging from mere irritation and perforation to severe ulceration and perforation.

The probable mechanism of mucosa damage due to aspirin (NSAID) could be explained on the following basis; the inhibition of prostaglandins synthesis via the arachidonic pathway (Vane, 1971; Soll *et al.*, 1991).

Synthetic non-steroidal anti-inflammatory (NSAIDs) like aspirin causes mucosal damage by interfering with prostaglandin synthesis, increasing acid secretion and block diffusion of  $H^+$  (Roa *et al.*, 1999). Aspirin blockade of cyclooxygenase-1 (COX-1) and (COX-2) results in reduction of prostaglandin synthesis. The interruption of prostaglandin synthesis results in impairment of mucosal

damage repair, thus facilitating mucosal injury (Burke *et al.*, 2006). Aspirin and related non-steroidal anti-inflammatory drugs and alcohol can aggravate or interfere with the healing of peptic ulcers.

Recently oxidative free radicals have been implicated in NSAID, ethanol, and cold restraint stress induced gastric injury (Vananenn *et al.*, 1991; Davies *et al.*, 1994; Perry *et al.*, 1986). McAlindon *et al.*, (1996) in their study had proposed that NSAIDs caused inflammation and neutrophil leading to free radical mediated gastric injury. Pihan *et al.*, (1987) also in their study reported the possible role of oxidative free radicals and lipid peroxidation in mediating NSAID induced gastric injury in albino rats. In parietal cells,  $H^+$  ion secretion is an oxidant process.  $H^+$  ion dissociates from  $H_2O$  or  $H_2CO_3$  also in an oxidant process.  $H^+$  is pumped out in exchange with  $K^+$  as an active transport process and  $Cl^-$  ion in exchange with  $HCO_3^-$  in basolateral membrane of parietal cells.  $Cl^-$  ion is then pumped and transported into gastric lumen. These increase oxidant process and increase hydrogen peroxide production. In presence of  $Cl^-$  and  $H_2O_2$ , hydrochloric acid will be formed and this is a very toxic oxidant. This will result in mucosal membrane lipid peroxidation and mucosal soreness and disruption (Moncada and Higgs, 1993). Lipid peroxidation and lipid derived products have been implicated in pathogenesis of a variety of diseases (Moriel *et al.*, 2000)

The results obtained indicating a reduction in gastric juice volume, gastric acidity and mean ulcer index and an increase in percent ulcer inhibition, clearly suggest that the extract of *Citrullus lanatus* apparently protected the gastric mucosa against aspirin induced ulceration in a dose dependent manner; comparable to the effect of Cimetidine a known histamine ( $H_2$ ) receptor antagonist used commonly in the management of peptic ulcer disease. Thus, the effect of the extract in this model suggests it may possess healing action probably by enhancing prostaglandin synthesis. Prostaglandins have protective effects against various gastric injury models (Wallace, 1992; Brzozowski *et al.*, 2005). Prostaglandins serve protective functions in the stomach by maintaining gastric micro circulation (Vane, 1971; Ferreira and Vane, 1974) and causing gastric secretion of bicarbonate (Garner *et al.*, 1979) and mucus (Menguy and Desbaillets, 1967). It seems likely that the rind of watermelon extract protects the tissues against oxidative damage through neutralization of released free radicals and inhibition of HCl secretion. This may be attributed to its phyto constituents; flavonoid and phenol. The best described property of almost every group of flavonoids is their capacity to act as antioxidants (Erukainure *et al.*, 2010). The flavones and catechins are perhaps the most powerful flavonoids for protecting the body against damage by reactive oxygen species (Sodipo *et al.*, 2000). The relationship between the total phenol content and antioxidant activity has been widely studied in different foodstuffs: Antioxidant activity of foodstuff significantly

increases with the presence of a high concentration of total phenol and flavonoid (Jayaprakasha *et al.*, 2001). Therefore, the high phenolic and flavonoid contents of the watermelon rinds suggest its possible high antioxidant potential.

The significant reduction in basal gastric secretion and ulcers formation by the extract after induction of gastric ulceration by aspirin suggests that the cytoprotective mechanism of the extract on gastric mucosa may involve direct reduction of gastric secretion. *The extract significantly* reduced gastric secretion and acidity, which might be due to the enhancement of mucus and HCO<sub>3</sub><sup>-</sup> secretion.

It has been earlier reported that nitric oxide inhibits gastric acid secretion in rats (Hasebe *et al.*, 2001). Watermelon rind is an edible source of citrulline, a compound vital for the production of nitric oxide. Its consumption increases the level of citrulline significantly (Rimando and Perkins-Veazie, 2005). It is therefore safe to propose that one of the possible mechanisms by which watermelon rind causes a decrease in gastric acid secretion is by increasing citrulline levels thereby stimulating an increase in nitric oxide production. This will lead to a decrease in gastric acid secretion as confirmed by previous reports by Brown *et al.*, 1993 and Kato *et al.*, 1998 which in turn accounts, at least in part, for the observed gastro protective effect of watermelon rind in aspirin-induced gastric ulceration.

It has been earlier reported that the rind of *Citrullus lanatus* has a gastro-protective effect on indomethacin-induced ulcer lesions in male rats by its cytoprotective property (Kolawole *et al.*, 2014).

The antiulcer activity of the rind of *Citrullus lanatus* might also be attributed to the presence of biological compounds such as triterpenoids, glycosides, saponins, tannins, and amino acids (Bandhopadhyay *et al.*, 2002). Triterpenoids and glycosides have been shown to inhibit gastric acid secretion and enhancement in gastric mucus content against several experimental ulcer models (Murakami *et al.*, 1990; Bandhopadhyay *et al.*, 2002). These plant constituents present in the rind might have the ability to protect against ulceration induced by aspirin.

Non-steroidal anti-inflammatory drugs (NSAIDs) such as aspirin have previously been reported to decrease antioxidant enzymes (SOD and Catalase) activity in rat stomach thereby causing gastric ulceration (Hallci *et al.*, 2005; Odagbabolu *et al.*, 2006). SOD activity was significantly increased in rats treated with *Citrullus lanatus* extract indicating that SOD plays an important role in preventing gastric ulcer by catalyzing the breakdown of highly reactive radical superoxide (O<sub>2</sub><sup>-</sup>) into oxygen and hydrogen peroxide (Zelko *et al.*, 2002; Gehan *et al.*, 2009).

Lipid peroxidation was estimated in terms of Malondialdehyde (MDA). *Citrullus lanatus* rind extract and Cimetidine produced significant reduction in MDA concentration suggesting that the antioxidant property of

*Citrullus lanatus* rind extracts (Erukainure *et al.*, 2010) may be powerful enough to prevent gastric ulcer through lipid peroxidation of gastric mucosa.

## CONCLUSION

Hydromethanolic extract of the rind of *Citrullus lanatus* offered some protection against aspirin induced gastric mucosal damage. The antioxidant compounds present in the extract play protective role against the production of reactive oxygen species and lipid peroxidation. The present study revealed that the rind of *Citrullus lanatus* has promising phytochemicals for the development of alternative treatment against gastric ulcer.

## REFERENCES

- Adesanya AO, Olaseinde OO, Oguntayo OD, Otulana JO, Adefule AK. (2011). Effects of Methanolic Extract of *Citrullus lanatus* Seed on Experimentally induced prostatic Hyperplasia. *Eur J Med Plants*.1(4):171-179.
- Akah PA, Nwabie AI (1994). Evaluation of Nigerian Traditional Medicinal Plants used for rheumatic inflammation disorders. *J Ethnopharmacol*. 42: 179-182.
- Akhtar MS, Munir M (1989). Evaluation of the gastric antiulcerogenic effects of *Solanum nigrum*, *Brassica oleracea* and *Ocimum basilicum* in rats. *J Ethnopharmacol*.27(1-2):163-76.
- Akuodor GC, Idris-Usman MS, Mbah CC, Megwas UA, Akpan JL, Ugwu TC, Okoroafor DO, Osunkwo JA (2010). Studies on anti-ulcer, analgesic and antipyretic properties of the ethanolic leaf extract of *Gongronema latifolium* in rodents. *Afri J Biotechnol*. 9 (5), 2316-2321.
- Appleyard CB, McCafferty DM, Tigley AW, Swain MG, Wallace JL. (1996). Tumor necrosis factor mediation of NSAID-induced gastric damage: role of leukocyte adherence. *Am J Physiol*. 270:G42-8.
- Bandyopadhyay U, Biswas K, Chatterjee R, Chattopadhyay I, Ganguly CK, Chakraborty T, Bhattacharya K, Banerjee RK.. (2002). Gastroprotective effect of Neem (*Azadirachta indica*) bark extract: Possible involvement of H(+)/K(+)ATPase inhibition and scavenging of hydroxyl radical. *Life Sci*.71(24) : 2845-65.
- Brown JF, Hanson PJ, Whittle BJ (1993). The nitric oxide donor, S-nitroso-N-acetyl-penicillamine, inhibits secretory activity in rat isolated parietal cells. *Biochem Biophys Res Commun*.195(3): 1354-9.
- Brzozowski T, Konturek PC, Konturek SJ, Brzozowska I, Pawlik T (2005). Role of prostaglandins in gastroprotection and gastric adaptation. *J Physiol Pharmacol*.56 Supp 5:33-55.
- Burke A, Smyth E, Fitzgerald GA (2006). Analgesic-Antipyretic Agents, Pharmacotherapy of Gout. In: Brunton, L.L., J.S. Lazo and K.L. Parker (Eds.), Goodman and Gilman. Pharmacological Bases of Therapeutics. 11th Edn., McGraw Co. Inco.,New York. 671-715
- Eamlamnam K, Patumraj S, Visedopas N, Thong- Ngam D. (2006). Effects of Aloe vera and sucralfate on gastric microcirculatory changes, cytokine levels and gastric ulcer healing in rats. *World J Gastroenterol*.12(13):2034-2039.
- Erukainure OL, Oke OV, Daramola AO, Adenekan SO, Umanhonlen EE (2010). Improvement of the Biochemical Properties of Watermelon Rinds Subjected to *Saccharomyces cerevisiae* Solid Media fermentation. *Pak J Nutr*. 9(8):806-809.
- Ferreira SJ, Vane R (1974). New aspects of the mode of actions of NSAIDs. *Ann. Rev. Pharmacol*. 14:57-70.
- Garner A, Flemstrom G, Heylings JR (1979). Effects of antiinflammatory agents and prostaglandins on acid and bicarbonate secretions in the amphibian- isolated gastric mucosa. *Gastroenterology*. 77(3):451-7.

- Gehan H, Magdy K.AH, Rauuia, SA (2009). Gastroprotective effect of simvastatin against indomethacin-induced gastric ulcer in rats: Role of nitric oxide and prostaglandins. *Eur J Pharmacol.* 607: 188-193
- Grabley S, Theierick R (1999). *Drug Discovery from nature* Springer: London. pp. 5-7.
- Hallci M, Odagbabolu F, Suleyman H, Cakir A, Aslam A, Bayir Y. (2005). Effect of water extract of *Usnea longissima* on antioxidant enzyme activity and mucosal damage caused by indomethacin in rats. *Phytomedicine* 12: 656-662.
- Hasebe K, Horie S, Komasa M, Yano S, Watanabe K (2001). Stimulatory effects of nitric oxide donors on gastric acid secretion in isolated mouse stomach. *Eur J Pharmacol.* 420(2-3):159-64.
- Heeba GH, Hassan MK, Amin RS (2009). Gastroprotective effect of simvastatin against indomethacin-induced gastric ulcer in rats: role of nitric oxide and prostaglandins. *Eur J Pharmacol.* 607(1-3): 188-193.
- Jainu M, Vijai Mohan K, Shyamala Devi CS. (2006). Gastroprotective effect of *Cissus quadrangularis* extract in rats with experimentally induced ulcer. *Indian J Med Res.* 123 (6):799–806.
- Kato S, Kitamura M, Korolkiewicz RP, Takeuchi K (1998). Role of nitric oxide in regulation of gastric acid secretion in rats: effects of NO donors and NO synthase inhibitor. *Br J Pharmacol.* 123(5):839–846.
- Kemidi I, Rakesh M, Vamshikrishna P, Niroop L, Baikuntha Prusti K. (2013). Protective effect of Ginger against aspirin induced ulcers in rats. *Int J Res Pharma and Biomed Sci.* 4(2):597-606.
- Kolawole TA, Dapper DV, Ojeka SO (2014). Ameliorative Effects of the Methanolic Extract of the Rind of *Citrullus lanatus* on Lead Acetate Induced Toxicity Semen Parameters and Reproductive Hormones of Male Albino Wistar Rats. *Eur J Medi Plants.* 4(9): 1125-1137
- Laine L, Takeuchi K, Tarnawski A (2008). Gastric mucosal defense and cytoprotection: bench to bedside. *Gastroenterology.* 135:41–60.
- Levi A, Thomas CE, Keinath AP, Wehner TC (2001). Genetic diversity among watermelon (*Citrullus lanatus* and *Citrullus colocynthis*) accessions. *Genet. Resour. Crop Evol.* 48:559-566.
- Lorke D (1983). A new approach to practical acute toxicity testing. *Arch Toxicol.* 54(4):275-287.
- Main IH, Whittle BJ (1975). Investigation of the vasodilator and antisecretory role of prostaglandins in the rat gastric mucosa by use of non-steroidal anti-inflammatory drugs. *Br J Pharmacol.* 53(2): 217-224.
- Menguy R, Desbaillets L (1967). Role of inhibition of gastric mucous secretion in the phenomenon of gastric mucosal injury by indomethacin. *Am J Dig Dis.* 12(9):862-6.
- Miller TA. (1987). Mechanisms of stress-related mucosal damage. *Am.J.Med.* 83: 8–14.
- Mulazim HB, Javed K, Samina Q, Zahid Q, Muhammad Z, Navid A, Irfan MB (2011). Comparative Gastroprotective Effects of Natural Honey, *Nigella sativa* and Cimetidine Against Acetylsalicylic Acid Induced Gastric Ulcer in Albino Rats. *J College of Physicians and Surgeons Pakis.* 21 (3): 151-156
- Murakami S, Kijima H, Isobe Y, Muramatsu M, Aihara H, Otonmo S, Baba K, Kozawa M (1990). Inhibition of gastric H<sup>+</sup>K<sup>+</sup>ATPase by chalcone derivatives xanthanogelol and 4-hydroxyderricin from *Angelica keiskei Kozidzumi*. *J Pharm Pharmacol.* 42 (10): 723-6.
- Naesdal J, Brown K (2006). NSAID-associated adverse effects and acid control aids to prevent them: a review of current treatment options. *Drug Saf.* 29:119–132.
- Odagbabolu F, Cakir A, Suleyman H, Aslam A, Bayir Y, Hallci M (2006). Gastroprotective and antioxidant effects of usnic acid on indomethacin induced gastric ulcer in rats. *J. Ethanopharmacol.* 103: 59-65.
- Rimando AM, Perkins-Veazie PM (2005). Determination of citrulline in watermelon rind. *J Chromatogr A.* 1078(1-2): 196–200.
- Roa CV, Maiti RN, Goel RK (2000). Effect of mild irritant on gastric mucosal offensive and defensive factors. *Med J Physiol Pharmacol.* 44(2):185-91
- Santucci L, Fiorucci S, Di Matteo FM, Morelli A (1995). Role of tumor necrosis factor alpha release and leukocyte margination in indomethacin-induced gastric injury in rats. *Gastroenterology.* 108(2):393–401.
- Sentu S, Debjani G (2008). Effect of ripe fruit pulp extract of *Cucurbita pepo* Linn. in aspirin induced gastric and duodenal ulcer in rats. *Indian J. Exp Biol.* 46: 639-645.
- Sofowora A (1993). Screening Plants for Bioactive Agents. In medicinal Plants and Traditional Medicinal in Africa. Spectrum Books Ltd Ibadan, 2ed, pp 134-156.
- Soll AH, Weinstein WM, Kurata J, McCarthy D (1991). Nonsteroidal anti-inflammatory drugs and peptic ulcer disease. *Ann Intern Med.* 114(4):307-19.
- Touhami M, Laroubi A, Elhabazi K, Loubna F, Zrara I, Eljahiri Y, Oussama A, Grases F, Chait A (2007). Lemon juice has protective activity in a rat urolithiasis model. *BMC urol.* 7:18.
- Vane JR (1971). Inhibition of prostaglandin synthesis as a mechanism of action for aspirin-like drugs. *Nat New Biol.* 231(25):232-5.
- Wallace JL (1992). Prostaglandins, NSAIDs and cytoprotection. *Gastroenterol Clin North Am.* 21(3):631–41.
- Zelko I, Mariani T, Folz R (2002). Superoxide dismutase multigene family: a comparison of the CuZn-SOD (SOD1), Mn-SOD (SOD2), and EC-SOD (SOD3) gene structures, evolution, and expression. *Free Radic Biol Med* 33 (3): 337–49