

## Case Report

# Super-refractory status epilepticus of unknown etiology with late onset and fatal outcome. Case report

Sapira Violeta<sup>1</sup>, Telehuz Anca<sup>2</sup>, Filip Iulia<sup>1</sup> and Lungu Mihaela<sup>1\*</sup>

### Abstract

<sup>1</sup>Galati Emergency Clinical County Hospital "Sf. Apostol Andrei", Romania

<sup>2</sup>Slobozia Emergency Country Hospital, Romania

First Author  
Sapira Violeta

E-mail: [violetasapira@yahoo.com](mailto:violetasapira@yahoo.com)  
Phone: +40765989333

\*Corresponding Author

Assoc. Prof. Lungu Mihaela  
E-mail: [micalungu@gmail.com](mailto:micalungu@gmail.com)  
[mihaelalungu17@yahoo.com](mailto:mihaelalungu17@yahoo.com)

Co-Authors

Telehuz Anca  
E-mail: [ciosy@yahoo.com](mailto:ciosy@yahoo.com)  
Phone: +40765944475

Filip Iulia  
E-mail: [Iulia.Filip85@yahoo.com](mailto:Iulia.Filip85@yahoo.com)  
Phone: +40742700323

Refractory status epilepticus and super-refractory status epilepticus are the most complex neurological manifestations requiring intensive treatment, because they are associated with high mortality. Diagnosis must be established immediately, simultaneously with the initiation of treatment. Also, a new term has recently been introduced : New-onset refractory status epilepticus - that defines refractory status epilepticus that it is installed in previously healthy patients without a clear cause of the initial examination. We present the case of a 48-year-old female patient without any medical history or chronic medication that came in the emergency unit with super-refractory status epilepticus of unknown etiology with late onset and who had fatal outcome

**Keywords:** Status epilepticus, Refractory status epilepticus, Super-refractory status epilepticus, New-onset refractory status epilepticus

### ABBREVIATIONS

RSE - refractory status epilepticus; SRSE - super-refractory status epilepticus; NORSE - new-onset refractory status epilepticus; SE - status epilepticus; GCS – Glasgow Coma Scale; HIV – human immunodeficiency virus; CT - computed tomography; MRI – magnetic resonance imaging; NMDA - N-metil D-aspartat; ANA – antinuclear antibodies; ANCA – antineutrophil cytoplasmic antibodies; EEG – electroencephalography; CSF – cerebrospinal fluid

## INTRODUCTION

Status epilepticus (SE) is a medical emergency that requires fast diagnosis and prompt treatment. SE is already diagnosed after a minimum seizure duration of five minutes, because the likelihood of spontaneous termination decreases after this time period; consequently, treatment should be initiated without further delay (Trinka et al, 2015; Gollwitzer et al, 2017). Lowenstein and Alldredge (1998) propose a more pragmatic definition of SE: „convulsions lasting over 5 minutes or two or more discreet seizures between which

there is incomplete recovery of consciousness”, which has been adopted by clinicians and researcher (Poblete et al, 2017). In most patients, the therapeutic regimen can control seizures. But a recent prospective study shows that up to 33% of SE cases are refractory to anticonvulsant medication (Delaj et al, 2017).

There is currently no consensus in the definition of refractory status epilepticus (RSE), which remain to be defined as a persistent SE after administration of one first-line medication (benzodiazepine administrate

intravenous) and one second-line medication (antiepileptic drug administered intravenously) (Marawar et al, 2018; Holtkamp et al, 2005). RES is more common in patients with acute cerebral injuries compared to patients known with epilepsy (Holtkamp et al, 2005, Novy et al, 2010).

The term "super-refractory status epilepticus" (SRSE) was introduced during the London-Innsbruck Colloquium on status epilepticus in 2011 (Shorvon et al, 2011). SRSE was defined "as continuous or recurrent seizures without normalization of consciousness for 24 hour or more despite administration of intravenous anaesthetic agent (midazolam, propofol, ketamine or phenobarbital) or recurrence of SE on weaning of intravenous anaesthetic" (Shorvon et al, 2011). These cases are more commonly seen in young patients, with altered consciousness at onset (Delaj et al, 2017). The most common causes of SRSE are autoimmune inflammatory conditions (Spatola et al, 2015; Gaspard et al, 2015).

New-onset refractory status epilepticus (NORSE) is a newly created term that defines a RSE that occurs in healthy patients, with no apparent cause of an initial assessment (Marawar et al, 2018; Poblete et al, 2017). The etiology of NORSE is frequently unknown (the term idiopathic or cryptogenic being used), but a significant percentage are secondary to autoimmune or paraneoplastic conditions (Gaspard et al, 2015).

Refractory and super-refractory status epilepticus is a treatment and diagnosing challenge, most of the time being grafted with increased mortality -between 15% and 54% ( Gollwitzer et al, 2017).

## CASE REPORT

We present the case of a 48-year-old patient without any medical history or chronic medication that came in the emergency department accusing the alteration of the general state, with respiratory failure (saturation of oxygen in arterial blood 85%), Glasgow coma scale 8 points, generalized tonico-clonic motor seizures, with sudden onset of symptoms in full health. The patient is occasionally consuming alcohol.

The patient is admitted in the intensive care unit where anticonvulsant with benzodiazepines therapy is initiated (intravenous midazolam). Because the seizures continued later the phenytoin is administered. Three hours after anticonvulsant treatment, the patient maintains generalized seizures so the orotracheal intubation with mechanical ventilation is decided. At this stage propofol is used with a loading dose of 3 mg/kg and subsequent infusion at a rate of 1mg/kg/hour.

At the same time, the patient's evaluation is performed in order to determine the SE etiology: cerebral computer tomography (CT) scan does not reveal recent changes; thoracic radiography that reveals a pronounced bilateral interstitial lung and normal heart; pelvic and abdominal

ultrasound that is within normal limits. Initially, blood tests reveal a moderate hepatic cytolysis syndrome (aspartate transaminase 68 U/L; alanine transaminase 51 U/L), but with negative viral markers, slightly increased alchoolemia (0,5 g/l). Also all tumoral markers are negative.

The attempt to establish the etiology of the SE, the lumbar puncture is performed with the biochemical examination of the cerebrospinal fluid (CSF) and the culture of CSF which were within normal limits: albumin 16mg/dl; chlorides 7,7 g%; glucose 97 mg/dl; leukocytes 6/mm<sup>3</sup>; negative Pandy reaction. The smear of CSF dose not reveal any germs and the culture of LCR is negative.

The recording of the electroencephalography(EEG) reveals an irritating background trace. Unfortunately, a continuous registration could not be achieved (although the optimal monitoring EEG time is not specified in the literature). Figure 1-3

The end of sedation is attempted but the reappearance of seizures requires maintaining sedation and urgently conducting a cerebral magnetic resonance imaging (MRI) which does not reveal any pathological changes (fig.1-3)

Investigations continue to find out the cause of seizures so that treatment can be established. As a result, blood test for syphilis, human immunodeficiency virus 1 and 2, antibodies antireceptor N-metil D-aspartat (NMDA) are made and all were negative. Also, thyroid hormones and immunological tests were made (inclusive antinuclear antibodies – ANA and antineutrophil cytoplasmic antibodies – ANCA) and were within normal limits.

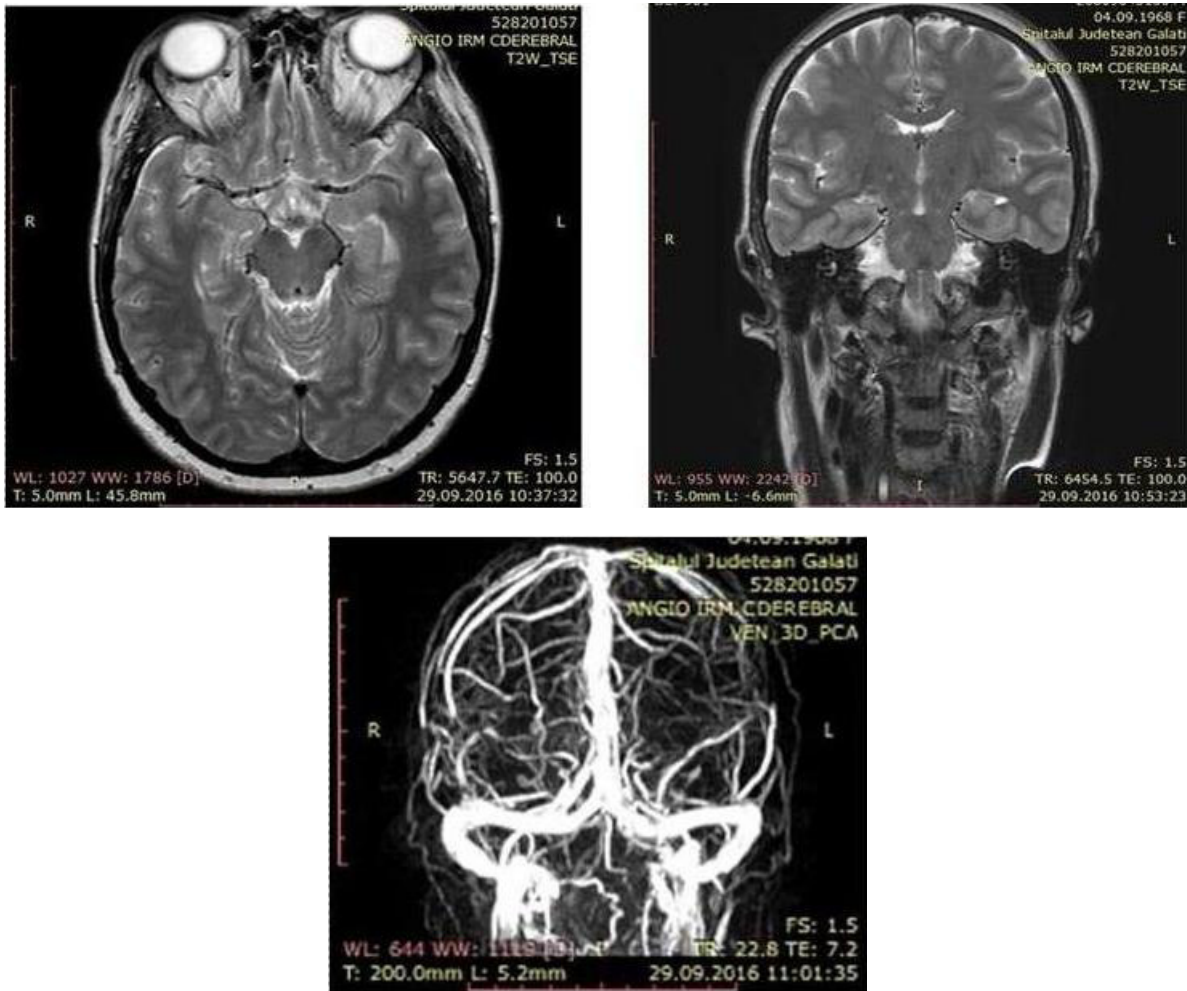
The patient's entourage states that she did not consume ethnobotanic substances and toxicological tests of blood and urine have also been negative.

Because seizures continue, despite repeated attempts to spot sedation, the following are decided: repeat cerebral CT with contrast and EEG monitorization that are still without any significant modification or epileptogenic center. A new lumbar puncture is performed with the examination of the cerebrospinal fluid that is also within normal limits.

The suspicion of limbic autoimmune encephalitis is raised. Until the results of NMDA antireceptor antibodies were available the patient is treated with large doses of steroids (1g of intravenous methylprednisolone) for 5 days.

A new attempt to suppress sedation is made but the seizures reappear, so intravenous immunoglobulins were administered for 5 days based on suspicion of an occult immunological etiology of new-onset refractory status epilepticus developed by the patient.

The investigations made do not allow the identification of the cause of the epilepticus super-refractory status. Unfortunately, the patient dies after 15 days of hospitalization and the autopsy did not detect the SE etiology.



**Figure 1-3.** Brain MRI and angiMRI does not reveal any pathological changes that can explain the super-refractory status epilepticus

## DISCUSSIONS

If the etiology assessment plan of SRSE, RSE, NORSE are similar, the treatment of SRSE it is a real challenge, because for now the therapeutic recommendations are based only on case reports, missing dates from randomized trials.

The goals pursued in the treatment of SRSE are the suppression of seizures, preventing recurrence, but also identifying, preventing and treating complications that may occur. All these measures are to be carried out simultaneously with the patient assessment to identify the etiology of SE. It is often necessary to determine the cause of SRSE because emergency etiology therapy can lead to the cessation of epileptic activity.

The current therapeutic protocols recommends the approach of patients with SRSE in a phased manner: so in stage 1 (the first 30 minute, early status epilepticus) the recommendations are for benzodiazepine therapy. If the seizure continues despite the treatment, stage 2 is being

installed (established status epilepticus), and conventional therapy involves the administration of intravenous antiepileptic medication, like: phenytoin, phenobarbital or valproate (Shorvon et al., 2011). Stage 3 (refractory status epilepticus) is reached if seizures continue over 120 minutes and general anesthesia is recommended.

For most patients this phased treatment regimen is enough to control crises. But in some cases crises continue or repeat. Under these circumstances it passes into super-refractory epilepticus status, which is defined as SE status epilepticus that continues or recurs 24 ore or more after the onset of anaesthetic therapy, including those cases that recur on the reduction or withdrawal of anaesthesia (Shorvon et al., 2011). SRSE current medical practice recommends the combination of anticonvulsant medication with general anesthesia. So far there are no studies to show which are the most appropriate and effective anticonvulsants medication, almost any antiepileptic drug can be used.

Since studies have demonstrated involvement of anti-NMDA receptor antibodies and the role of inflammation in epileptogenesis (Vezzani et al., 2009; Maroso et al., 2010; Zurolo et al., 2011; Gollwitzer et al., 2017) it is currently commonly used in the treatment of SRSE immunotherapy with corticoids, intravenous immunoglobulins or plasma exchange. Immunotherapy is used even in the absence of any apparent immunological cause for the epilepticus status, because many cryptogenic cases could be caused by occult immunological disorders with antibodies that have not yet been identified, as one can suspect in the case presented in this paper.

It is usually started with steroids in high doses (intravenous, 1g methylprednisolone) for 3 to 7 days. If there is no response to corticotherapy, immunoglobulin can be administered (0,4 g/kg/day for 5 days; Shorvon et al., 2011) or perform plasma exchange.

The patient should also be monitored for the occurrence of rhabdomyolysis and acute renal insufficiency which may influence the choice of anticonvulsant.

All the above-mentioned therapeutic steps were applied in the presented case, but unfortunately without any positive result, which eventually led to exitus for this patient. Maybe if the NORSE etiology was identified, the end would have been different. The etiology has not been identified at autopsy either. In a study evaluating 130 cases of NORSE (Gaspard et al., 2015), 52% of them remained cryptogenic despite some exhaustive evaluations. In these cases neuropathological evaluation by biopsy or autopsy were still inconclusive (Wilder-Smith et al., 2005; Costello et al., 2009).

## CONCLUSIONS

Super-refractory epilepticus status is a serious medical condition striking a high mortality. There is still much to be learned regarding the diagnosis and therapy of SRSE. There is currently little data on safety, efficacy and the results of different therapeutic regimens. The primary objective of SRSE treatment is actually identifying the cause and treating it if possible.

**Informed Consent:** The patient's informal approval has been obtained and recorded in the chart.

**Author contributions:** All the authors have equal contributions in this presentation.

**Ethical approval:** This article does not contain any studies with human participants performed by any of the authors.

**Financial disclosure:** none

**Grant information:** This article did not receive any specific grant from funding agencies in the public, commercial or not-for-profit sectors.

## ACKNOWLEDGEMENT

Thanks go to the proof readers for providing language help and for proof reading the article.

## REFERENCES

- Costello DJ, Kilbride RD, Cole AJ (2009). Cryptogenic New Onset Refractory Status Epilepticus (NORSE) in adults: infectious or not? *J Neurol Sci*;277:26-31.
- Delaj L, Novy J, Ryvlin P et al (2017). Refractory and super-refractory status epilepticus in adults: A 9-year cohort study. *Acta Neurol Scand*; 135: 92–99
- Gaspard N, Foreman BP, Alvarez V et al (2015). New-onset refractory status epilepticus: Etiology, clinical features, and outcome. *Neurology*; 85: 1604–1613
- Gollwitzer S, Hamer HM (2017). The Treatment and Prognosis of Refractory and Super-Refractory Status Epilepticus. *Neurology International Open*; 1: E204–E210
- Holtkamp M, Othman J, Buchheim K, Meierkord H (2005). Predictors and prognosis of refractory status epilepticus treated in a neurological intensive care unit, *Journal of Neurology, Neurosurgery & Psychiatry*, vol. 76, no. 4, pp. 534–539.
- Lowenstein DH, Aldredge BK (1998). Status epilepticus. *N Engl J Med*; 338:970-6
- Marawar R, Basha M, Mahulikar A, Desai A, Suchdev K, Shah A (2018). Updates in Refractory Status Epilepticus. *Critical Care Research and Practice Volume*, Article ID 9768949, 19 pages
- Maroso M, Balosso S, Ravizza T, Liu J, Aronica E, Iyer AM, et al (2010). Toll-like receptor 4 and high-mobility group box-1 are involved in ictogenesis and can be targeted to reduce seizures. *Nat Med*; 16: 413–9.
- Novy J, Logrosino G, Rossetti AO (2010). Refractory status epilepticus: A prospective observational study. *Epilepsia*; 51: 251–256
- Poblete R, Sung G (2017). Status Epilepticus and Beyond: A Clinical Review of Status Epilepticus and an Update on Current Management Strategies in Super-refractory Status Epilepticus. *Korean J Crit Care Med*, May 32(2):89-105
- Shorvon S, Ferlisi M (2011). The treatment of super-refractory status epilepticus: A critical review of available therapies and a clinical treatment protocol. *Brain*; 134: 2802–2818
- Spatola M, Novy J, Du Pasquier R et al (2015). Status epilepticus of inflammatory etiology: A cohort study. *Neurology*; 85: 464–470
- Trinka E, Cock H, Hesdorffer D et al (2015). A definition and classification of status epilepticus—Report of the ILAE Task Force on Classification of Status Epilepticus. *Epilepsia*; 56: 1515–1523
- Vezzani A, Balosso S, Aronica E, Ravizza T (2009). Basic mechanisms of status epilepticus due to infection and inflammation. *Epilepsia*; 50 (Suppl 12): 56–7
- Wilder-Smith EP, Lim EC, Teoh HL, Sharma VK, Tan JJ, Chan BP, et al (2005). The NORSE (new-onset refractory status epilepticus) syndrome: defining a disease entity. *Ann Acad Med Singapore*; 34:417-20.
- Zurolo E, Iyer A, Maroso M, Carbonell C, Anink JJ, Ravizza T, et al (2011). Activation of toll-like receptor, RAGE and HMGB1 signalling in malformations of cortical development. *Brain*; 134: 1015–32.