

Original Research Article

Efficiency of cone-beam computed tomography images for evaluation of the position and dimensions of nasopalatine canal

Farzad Esmaeili¹, Ehsan Hashemi², Ali Zarandi^{3*}

Abstract

¹Assistant Professor, Department of Oral and Maxillofacial Radiology, Faculty of Dentistry, Tabriz University of Medical Sciences, Iran

²Doctor of dentist, Faculty of Dentistry, Tabriz University of Medical Sciences, Iran

³Assistant Professor, Department of Periodontics, Faculty of Dentistry, Tabriz University of Medical Sciences, Tabriz, Iran

*Corresponding Author's Email:
dr.alizarandi@gmail.com
Tel.: 00984133355965

Due to the importance of determination of nasopalatine canal region and its characteristics in the implant surgeries, this study was designed to analyze the position and dimensions of nasopalatine canal in the cone-beam computed tomography (CBCT) images. CBCT images of 76 patients were evaluated. The diameter of canal in 3 points (incisive foramen, nasal foramen, and middle of canal) and length of canal were measured and distance of canal from maxillary central incisor root in 3 points (incisive foramen, root apex, and mid root of central incisors) was recorded by two expert radiologists. The nasopalatine canal showed a large variability in position and dimensions. Mean length of the canal in males was greater than that in females and this difference was statistically significant ($P < 0.05$). Gender of the included patients had a statistically significant influence on the canal diameter in the middle of the incisive canal and the mean values were higher in male subjects ($P < 0.05$). The mean canal diameter in the nasal and incisive foramens and the mean distance from the maxillary central incisor root showed no significant difference between males and females ($P > 0.05$). The age of the patients had no significant influence on the evaluated parameters ($P > 0.05$). According to the results, gender is an important factor that can affect incisive canal dimensions. Hence, clinicians should do a careful analysis using the CBCT images before performing dental implant surgeries in the premaxillary region. Advantage of cone-beam computed tomography (CBCT) images in determination of nasopalatine canal region and its characteristics in the implant surgeries

Keywords: Cone-beam computed tomography, Dental implant, Nasopalatine canal

INTRODUCTION

In the anterior maxilla, nasopalatine canal and incisive foramen have been known as the important landmarks for dental implant surgeries (Greenstein, Cavallaro et al. 2008). With the increasing demand for restoration of an edentulous maxilla by means of dental implants, the importance of the nasopalatine canal is highlighted and the identification of anatomical diversity of dimension and morphology of the nasopalatine canal is critically emphasized (Chandler and Gray 1996, Kraut and Boyden

1998, Cavalcanti, Yang et al. 1999, Bornstein, Balsiger et al. 2011). Risks and clinical side effects in surgery on the nasopalatine canal and neurovascular disorders was not discussed (Bornstein, Balsiger et al. 2011); however, Filippi et al. (1999) explained that during the first week after the operation, objective sensory disorders were found in all of the patients, but after four weeks no neurological problems could be detected in any patient (Filippi, Pohl et al. 1999). Due to the close relation of the

nasopalatine duct and the central incisor root, accurate radiographic analysis is necessary for dental implants. Diagnostic image of maxillary bone was prepared by panoramic and 2-D cross-sectional imaging and spiral computed tomography with multiplanar reformatting (Harris, Buser et al. 2002). Conventional radiography techniques could not detect anatomical structures, as the disadvantages of CT, and the method related to patients undergoing to x-ray imaging were highlighted (Temmerman, Hertele et al. 2011). In addition, cone-beam computed tomography (CBCT) systems have been aimed at imaging of hard tissues of the maxillofacial region. With resolutions of images of high diagnostic quality, scanning times have been shortened (10-70 seconds) and radiation dosages apparently are up to 15 times lower than conventional CT scans (Scarfe, Farman et al. 2006, de Oliveira-Santos, Rubira-Bullen et al. 2013). This study was designed to analyze the position and dimensions of the nasopalatine canal in CBCT images, because increasing the accessibility of this method would offer dental clinicians to provide a 3-dimensional image of the maxillofacial skeleton with minimal distortion.

METHODS

In this study, maxillary CBCT images of 76 patients who had been referred to the Radiology Department of Dental faculty, Tabriz University of medical sciences, during one year (2011-2012), were investigated. Samples were randomly selected ($\alpha = 0.05$, power =80%). Acceptable differences for each variable, canal lengths, canal diameter, and canal distance with central incisors were calculated and the large sample size related to canal diameter, namely 76 samples, was selected.

Inclusion criterion was determined as having the maxillary central incisors and exclusion criteria included any artifact areas in images and pathologies such as detection of nasopalatine duct cyst in the incisor canal. Total CBCT images were taken using a Newtom VG CBCT device (QR Srl Company, Verona, Italy). Scans were analyzed by an NNT viewer, version 2.21 (Imagework, NY, USA) by two expert radiologists. Images were detected in monitor CRT (Cathode Ray tube:17-inch, 32-bit, 256-colors and 1204x768 resolution). Thickness of slices was 1mm and images were obtained in cross sectional views. Canal lengths from the incisive foramen to the nasal foramen, and the canal diameter in three points (incisive formation, nasal formation, and middle of canal) were determined. Also, distance of the canal from the central teeth was measured in three points (incisive foramen, apex of central teeth, and middle point of these two points) (Figure 1). The results were analyzed with respect to gender and age by descriptive analyses (% , frequency, Mean (SD) via SPSS version16.0).

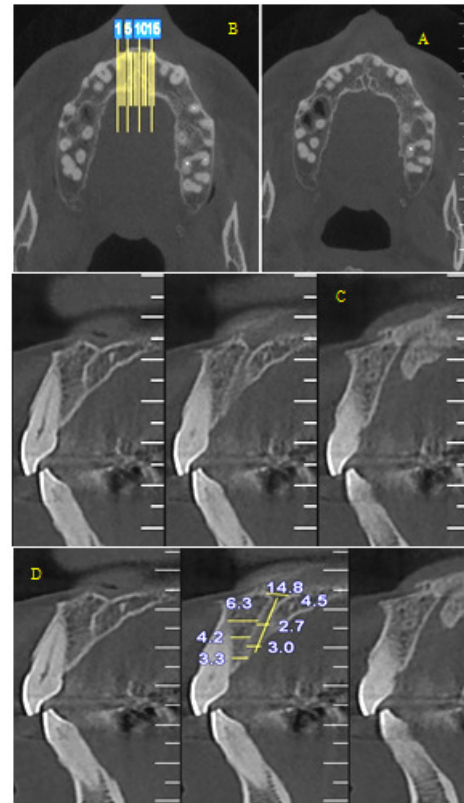


Figure. 1. A: Axial image of nasopalatine canal, B: Thickness of slices (1mm), C & D: Measurement of height and diameter of canal in cross-sectional CBCT images

Pearson correlation measures were reached by the agreement between two radiologists.

RESULTS

The mean \pm SD of nasopalatine canal diameter with respect to age and gender was shown in Table 1. Statistical analyses for comparing variables between groups by t-test, Pearson correlation coefficient, and ANOVA was indicated in Table 2. The subjects had a normal distribution pattern according to the results.

An independent t-test was used to compare the diameter of canal at three different levels in males and females. This test showed that mean of canal length and diameter in middle point in males was higher than that in females ($P < 0.05$). The mean of canal diameter in nasal, incisive, and middle was not statistically significant ($P > 0.05$). Comparing the variables in age groups by the ANOVA test indicated that the mean canal dimension was equal in these groups ($P > 0.05$). Mean canal diameter in nasal, middle, and incisive was high in 22-32 years, 53-63 years, and 43-52 years age groups, respectively. The mean distance from the central's apex and middle of root was higher in the 34-42 years age

group and in the incisive area in the 22-32 years age group.

DISCUSSION

Successful implantation requires enough palatal bone and apical root ratio for primary implant stability (Kan and Rungcharassaeng 2000). When the maxillary central incisor is subjected, it is important that nasopalatine canal be evaluated during the treatment process. Due to close anatomical relation between nasopalatine canal and maxillary central incisor root, accurate radiological assessment is important during the dental implant. In this study, two radiologists evaluated 76 CBCT images for which the Pearson correlation coefficient was more than 0.8 and this showed a high correlation between their determinations. This finding was in agreement with Thakur et al. (2013) that reported an important variability in the anatomy and morphology of the nasopalatine canal which can be related to the investigated patients with respect to their gender and genetic diversity (Thakur, Burde et al. 2013).

In this study, the mean of incisive canal diameter was 3.5 (9.4) mm which was lower than the measurement described by Mraiwa et al. (4.6 mm) (Mraiwa, Jacobs et al. 2004), while compatible with measurement described in Liang et al. and Thakur studies (Liang, Jacobs et al. 2009). The previous data demonstrated that the foramen incisive diameter was less than 6 mm in normal status and in the pathologic status, it raised to more than 10 mm (Mraiwa, Jacobs et al. 2004); however, in our study, it was between 1.5- 5.4 mm.

Besides, in the other studies nasopalatine canal length was explained with a mean of 8.1 (3.4), 9.9 (2.6), and 10.08 (2.25) (Mraiwa, Jacobs et al. 2004, Liang, Jacobs et al. 2006, Thakur, Burde et al. 2013). Mean of canal length in our study was 13.6 mm (2.4) which was in line with other studies with a mean of 12 mm (15.8- 8.4) (Song, Jo et al. 2009).

In the present study, the dimensions and conditions of nasopalatine canal differences in the investigated age groups was not statistically significant. This difference may be linked to the population studies which were unlike previous researches (Mardinger, Namani-Sadan et al. 2008, Liang, Jacobs et al. 2009, Bornstein, Balsiger et al. 2011). The increasing canal size shown in the present study may be associated with patients edentulous not with age changes. On the other hand, the mean of nasopalatine canal distance to the maxillary central incisor root was significantly shorter in the youngest age group than in other groups (Chatriyanuyoke, Lu et al. 2012). According to our results, canal length in males was high in comparison with females and this difference was statistically significant and equal to the reported results from Liang et al. and Thakur et al. (Liang, Jacobs et al. 2009, Thakur, Burde et al. 2013) and this is due to

the relatively larger size of the craniofacial structure observed in men.

Significant differences were found between male and female readings in the middle canal diameters with the results being higher in males. This result was well-matched with Guncu et al. results in that they suggested gender related differences in anatomic features of the incisive canal and surrounding buccal bone. In addition, other characteristics including crestal canal diameter, buccal bone length, and thickness could be different in other countries (Guncu, Yildirim et al. 2013). Similarly, Bornstein et al. demonstrated that the age of the patients showed a significant influence only on the length of the nasopalatine canal; however, with respect to the gender of patients, differences of mean canal diameter were not significant (Bornstein, Balsiger et al. 2011). On the contrary, in another study, mean of nasopalatine canal distance to the maxillary central incisor root was significantly more in males than in females at the mid-root level but not at the apex level. At the mid-root level as well as the apex level, distance was also significantly shorter for the youngest age group compared to the other age groups (Chatriyanuyoke, Lu et al. 2012).

CONCLUSION

According to the results, gender was important factor that can affect incisive canal dimensions. Hence clinicians should do a careful analysis using CBCT images and diameter of the incisive foramen (less than 6 mm) before performing dental implant surgeries in premaxillary region.

REFERENCES

- Bornstein MM, R Balsiger, P. Sendi, T von Arx (2011). "Morphology of the nasopalatine canal and dental implant surgery: a radiographic analysis of 100 consecutive patients using limited cone-beam computed tomography." *Clin Oral Implants Res* 22(3): 295-301.
- Cavalcanti MG, J. Yang, A. Ruprecht, MW Vannier (1999). "Accurate linear measurements in the anterior maxilla using orthoradially reformatted spiral computed tomography." *Dentomaxillofac Radiol* 28(3): 137-140.
- Chandler NP, A. Gray (1996). "Patent nasopalatine ducts: a case report." *N Z Dent J* 92(409): 80-82.
- Chatriyanuyoke P, Ci Lu, Y. Suzuki, JL Lozada, K. Rungcharassaeng, JY. Kan, CJ Goodacre (2012). "Nasopalatine canal position relative to the maxillary central incisors: a cone beam computed tomography assessment." *J Oral Implantol* 38(6): 713-717.
- de Oliveira-Santos C, IR Rubira-Bullen, SA. Monteiro, JE. Leon, R. Jacobs (2013). "Neurovascular anatomical variations in the anterior palate observed on CBCT images." *Clin Oral Implants Res* 24(9): 1044-1048.
- Filippi A, Y. Pohl, U. Tekin (1999). "Sensory disorders after separation of the nasopalatine nerve during removal of palatal displaced canines: prospective investigation." *Br J Oral Maxillofac Surg* 37(2): 134-136.
- Greenstein G, J. Cavallaro, D. Tarnow (2008). "Practical Application of Anatomy for the Dental Implant Surgeon." *Journal of Periodontology* 79(10): 1833-1846.

- Guncu GN, YD Yildirim, HG Yilmaz, P. Galindo-Moreno, M. Velasco-Torres, K. Al-Hezaimi, R. Al-Shawaf, E. Karabulut, H. L. Wang, TF Tozum (2013). "Is there a gender difference in anatomic features of incisive canal and maxillary environmental bone?" *Clin Oral Implants Res* 24(9): 1023-1026.
- Harris D, D. Buser, K. Dula, K. Grondahl, D. Haris, R. Jacobs, U. Lekholm, R. Nakielny, D. van Steenberghe, P. van der Stelt (2002). "E.A.O. guidelines for the use of diagnostic imaging in implant dentistry. A consensus workshop organized by the European Association for Osseointegration in Trinity College Dublin." *Clin Oral Implants Res* 13(5): 566-570.
- Kan JY, K. Rungcharassaeng (2000). "Immediate placement and provisionalization of maxillary anterior single implants: a surgical and prosthodontic rationale." *Pract Periodontics Aesthet Dent* 12(9): 817-824; quiz 826.
- Kraut RA, DK Boyden (1998). "Location of incisive canal in relation to central incisor implants." *Implant Dent* 7(3): 221-225.
- Liang X, R Jacobs, W. Martens, Y. Hu, P. Adriaenssens, M. Quirynen and I. Lambrichts (2009). "Macro- and micro-anatomical, histological and computed tomography scan characterization of the nasopalatine canal." *J Clin Periodontol* 36(7): 598-603.
- Liang X, R. Jacobs, I. Lambrichts (2006). "An assessment on spiral CT scan of the superior and inferior genial spinal foramina and canals." *Surg Radiol Anat* 28(1): 98-104.
- Mardinger O, N Namani-Sadan, G Chaushu, D. Schwartz-Arad (2008). "Morphologic changes of the nasopalatine canal related to dental implantation: a radiologic study in different degrees of absorbed maxillae." *J Periodontol* 79(9): 1659-1662.
- Mraiwa N, R. Jacobs, J. Van Cleynenbreugel, G. Sanderink, F. Schutyser, P. Suetens, D. van Steenberghe, M. Quirynen (2004). "The nasopalatine canal revisited using 2D and 3D CT imaging." *Dentomaxillofac Radiol* 33(6): 396-402.
- Scarfe WC, AG Farman, P. Sukovic (2006). "Clinical applications of cone-beam computed tomography in dental practice." *J Can Dent Assoc* 72(1): 75-80.
- Song WC, DI Jo, JY Lee, JN Kim, MS Hur, KS Hu, HJ Kim, C Shin, KS Koh (2009). "Microanatomy of the incisive canal using three-dimensional reconstruction of microCT images: an ex vivo study." *Oral Surg Oral Med Oral Pathol Oral Radiol Endod* 108(4): 583-590.
- Temmerman A, S Hertele W. Teughels, C. Dekeyser, R. Jacobs, M. Quirynen (2011). "Are panoramic images reliable in planning sinus augmentation procedures?" *Clin Oral Implants Res* 22(2): 189-194.
- Thakur AR, K. Burde, K. Guttal, VG Naikmasur (2013). "Anatomy and morphology of the nasopalatine canal using cone-beam computed tomography." *Imaging Sci Dent* 43(4): 273-281.