

Case Report

Twisted Ovarian Fibroma, A Rare Disease

Ioannis K. Thanasas*, Tilemahos Karalis and Konstantina Balafa

Abstract

Department of Obstetrics –
Gynecology of General Hospital in
Trikala, Trikala, Greece

*Corresponding Author's E-mail:
thanasasg@hotmail.com
Tel.: 2431029103 / 6944766469

This case report is about the surgical treatment of a patient with twisted ovarian fibroma. A patient in menopausal age with a mentioned history of a uterine fibroma came to the emergency room of our hospital with acute abdomen. Physical examination revealed the presence of a solid painful pelvic mass possibly arising from the right adnexa. Imaging control reinforced the diagnosis of twisted adnexal mass and a total abdominal hysterectomy with bilateral salpingo – oophorectomy was performed. Histological examination of the surgical specimen confirmed the ovarian fibroma. After a 5-day hospitalization and a smooth post-operative course, the patient was discharged. In this paper a literature preview of ovarian fibromas as concern as the diagnosis and the treatment methods, based on current data, is discussed.

Keywords: Ovarian fibroma, twisted, diagnosis, treatment.

INTRODUCTION

The sex cord – gonadalstromal tumors of the ovaries derive from the inseparable components of the developing gonad and especially from the primitive sex cord or the specialized ovarian substrate. These tumors are uncommon. It is about 8% of total ovarian tumors. The most common ovarian sex – cord stromal (gonadostromal) tumors are thecomas, fibromas and granulosa cell tumors. Androblastomas, gynandroblastoma and the rest of these tumors are uncommon (Mansoor and Jezaan, 2015).

Ovarian fibromas are described for first time by Young and Scully in 1983 (Young and Scully, 1983). Ovarian fibromas are the most common solid ovarian tumors (1 – 4%) and usually occur to middle aged women (Nigam et al, 2013). Most of the cases the pre-surgical diagnosis is difficult. Commonly, they are misdiagnosed as uterine fibromas due to the same pathology, the same complications and the same clinical and ultrasonographical findings (Gogineni S et al, 2013; Najmi et al, 2014). In some cases is possible to misdiagnosed as malignant ovarian tumors because there is ascites and elevated blood-serum levels of cancer antigen 125 (Ca

125) (Macciò et al, 2014). Ovarian fibromas occur between 20 and 65 years old with mean ages in the fifth and sixth decades (Yen et al, 2013; Taskin et al, 2014), Ovarian fibroma can be bilateral in 4-8% of patients and multiple in 10% of cases (Cambruzzi et al, 2010), especially in Gorlin syndrome (Pirschner et al, 2012; Rambocas and Murphy, 2013), or associated with pleural effusion and ascites in Meigs' syndrome (Riker and Goba, 2013; Yazdani et al, 2014).

In this paper a literature preview of ovarian fibromas as concern as the diagnosis and the treatment methods, based on current data, is discussed.

CASE REPORT

This case report is about a menopausal woman 52 years old who presented to the emergency department of our hospital with complaints of acute abdominal pain for the past 24 hours, vomiting and fever (up to 38.2°C) the last hours. The pain was in the lower abdomen especially in the right lower quadrant. From her medical history it was

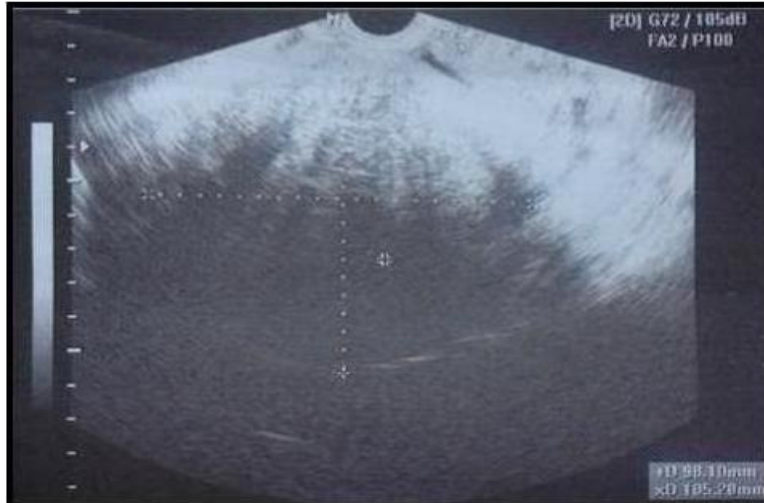


Figure 1. Vaginal ultrasound of twisted ovarian fibroma (our case).

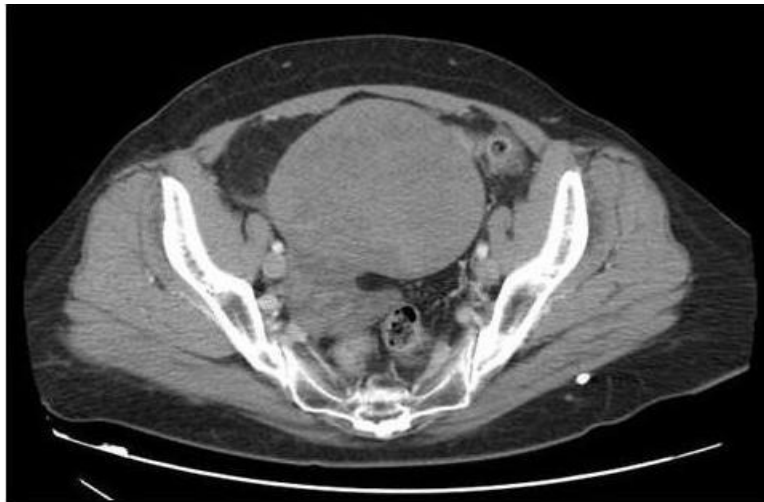

Figure 2. Computed tomography showing the twisted ovarian fibroma (our case).

mentioned a known uterine fibroma which was firstly diagnosed a decade ago. Her hereditary history was without any pathology. Physical examination revealed a painful pelvic mass in the right adnexa. Based to the mentioned uterine fibroma and the clinical suspicion of adnexal mass, the patient underwent to imaging control. Abdominal ultrasonography was not that diagnostical. Vaginal ultrasonography showed a solid, distinct, homogeneous mass in the right ovary without the presence of an invasive mass from the uterus (Figure 1). Pelvic computed tomography (Figure 2) confirmed the ultrasound findings without the exclusion of apedunculated subserosal uterine fibroid. Emergency lab tests: Ht 29.3%, Hb 9.9gr/dl, PLT: 236×10^3 /ml, WBC 13.94×10^3 /ml, NEUT 81%, CRP 23.06 mg/dl. The coagulating mechanism, the biochemical blood test as well as the urine test was clear.

When the pre-operational check was completed, surgical treatment with research laparotomy was determined. Intraoperative (Figure 3), after the opening of the abdominal wall and the peritoneum with middle vertical incision, it was found a solid ovarian mass with extensive ischemic necrosis with maximum diameter about 10 cm that was not adhered to the adjacent tissues (Figure 4). Total hysterectomy with bilateral salpingo – oophorectomy were performed. According to pathological and immunohistochemical findings, the diagnosis of ovarian fibroma was confirmed (Figure 5). The cytological examination of the peritoneal washing was negative for malignancy. After 5 days of hospitalization and a smooth post – operative course, the patient was discharged from our clinic with the recommendation of follow up at the out patient clinic.

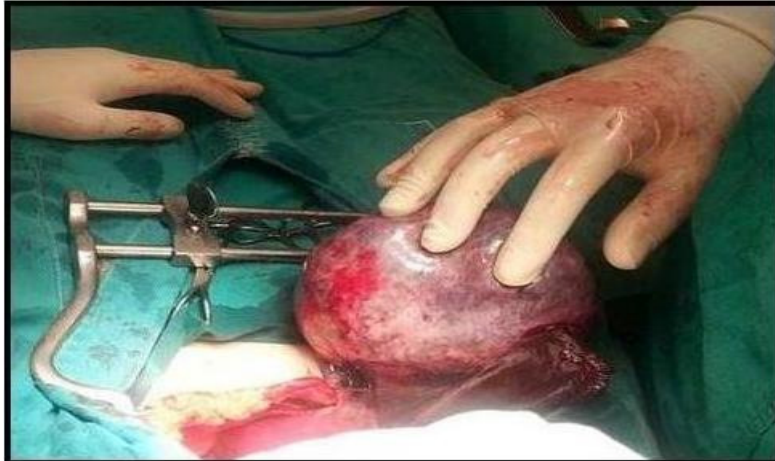

Figure 3. Intraoperative picture showing the twisted ovarian fibroma (our case).

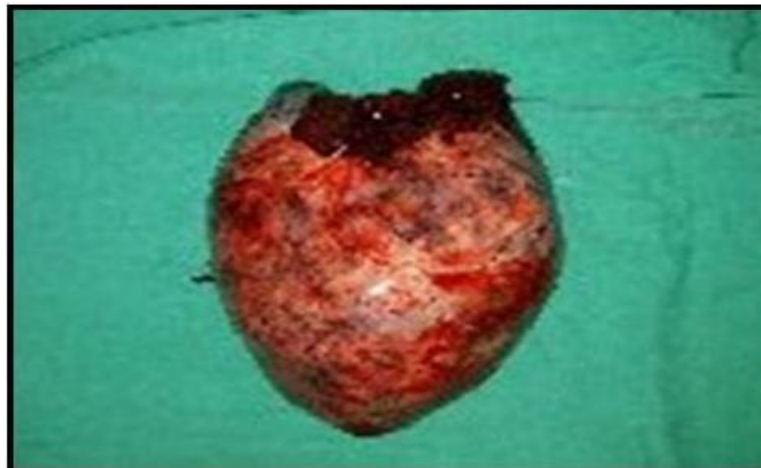

Figure 4. Macroscopic appearance of the resected ovarian fibroma (our case).

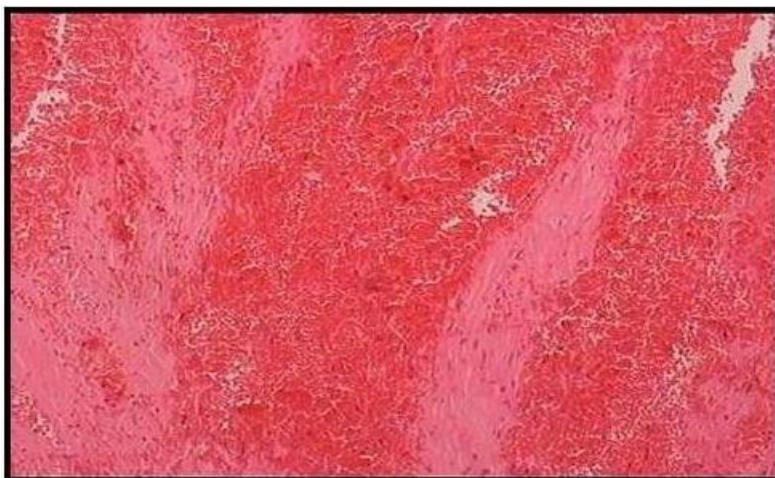

Figure 5. Histopathology of ovarian fibroma (our case). The presence of spindle cell isoblastic, which are arranged in a bundle-like and storiform growth pattern, with mild hyalinization of the stroma.

DISCUSSION

Clinical diagnosis of ovarian fibroid tumors is usually difficult. During the pre – operative examination, ovarian fibroid tumors are in most cases misdiagnosed as fibroid tumors of the uterus (like in our case) or as malignant tumors of the ovaries. Ovarian fibrosis that derive from the ovarian stroma might have hormonal activity and induce premalignant lesions in the endometrium (Genç et al, 2015). Even though most patients present no symptoms and diagnosis is in most cases incidental, sometimes fibroids in one or both of the ovaries can be presented with non – specific symptoms, like abdominal distention, abdominal bloating, undefined abdominal discomfort and abdominal pain. In rare occasions patients can experience dysuric symptoms (Son et al, 2011). In extreme rare cases (like the case above) these tumors can undergo torsion and necrosis (Mak et al, 2009). The solid nature of ovarian fibroids, their relation with ascites and pleural effusion, the weight loss, the abdominal distention that relate to large and rapidly growing ovarian tumors and the elevated serum levels of Ca125 due to tissue necrosis and inflammation need further diagnostic investigation, in order to exclude ovarian malignancy (Shinagare et al, 2012). Malignant ovarian neoplasms and fibroids of the uterus are the most important pathological entities that must be taken into consideration in the differential diagnosis of the ovarian fibroids (Cho et al, 2013).

In contrast to the clinical criteria, the contribution of contemporary imaging methods in the diagnosis of ovarian fibrosis seems to be more determinant. Transabdominal ultrasonography, and particularly transvaginal ultrasonography and Doppler ultrasound imaging of the pelvis have been well established nowadays as the gold standard methods for pelvic masses, but in the diagnostic approach of the ovarian fibroids there are still some limitations that concerns their differential diagnosis with other ovarian tumors (Yen et al, 2013). Paladini et al. in their analysis of the results of their study noticed that most of the fibroids are round shaped, oval or lobed solid tumors that relate with the presence of fluid in the douglas pouch. Additionally, they published that it's important to exclude the possibility of ovarian cancer in every patient with fibroid that coexist with fluid in the douglas pouch or ascites and elevated serum levels of Ca125 (Paladini et al, 2009). On the other hand, at 2006 Daponte et al. published that in the case of ovarian fibroid torsion, necrosis and inflammation can also result in elevation of the serum level of Ca125 and elevated inflammatory markers (Daponte et al, 2006). MRI constitutes a diagnostic tool with excellent results in imaging of soft tissues. Nowadays MRI is widely used in the investigation of adnexal masses that can't be well defined by ultrasonography. Magnetic resonance imaging of ovarian fibroids depends on the size of the tumor, the capsule and the degenerative changes (Jung et al, 2005).

CT scan is difficult to define ovarian fibroid from other ovarian masses, some of which are possible to have signs of malignancy. Ovarian fibroids can be imaged with many different ways in CT. Ovarian fibroid are usually presented as ipsilateral adnexal solid tumors. Presence of ascites and pleural effusion relate to the diagnosis of Meig syndrome (Liu et al, 2012). Diagnostic criteria that demonstrate ovarian fibroid torsion include a solid adnexal mass that after the torsion is located in the midline and displaces the uterus from the location of the diseased ovary (Chang et al, 2008; Zhang et al, 2015). In addition, calcification, and mucoid or cystic degeneration is possible to happen, specifically in tumors growing rapidly. It is estimated that the possibility of torsion of the diseased adnexa relates to the size of the tumor. At 2009 Mak et al. demonstrated that the lack of vascularization in the ovarian tumor is the most objective diagnostic criterion to detect torsion at the adnexa of the same side (Mak et al, 2009). More recently, at 2013 Yen et al. during the analysis of the results of their study concluded that vascularization of ovarian tumors that can be imaged by Doppler ultrasonography, MRI and CT is typically founded in fibromas and fibrothecomas of the ovary. Also In the same study, they published about cystic adnexal masses that, even though at first site they are considered to be of epithelial origin, the possibility of presence of a stromal tumor can't be ignored (Yen et al, 2013).

Therapy of ovarian fibrosis is surgical. Adnexectomy with laparotomy or laparoscopy is the surgical method of choice in women that want to retain their fertility. Total hysterectomy and bilateral adnexectomy is the best surgical choice in older women (our case). Despite all the advantages of the laparoscopic approach, most surgeons nowadays hesitate to use laparoscopy as a therapeutic method for ovarian fibroids. Challenges that usually occur during surgical excision of the ovarian tumor and the difficulty in the preoperative diagnosis of the disease don't permit the safe, without peritoneal dissemination – inflammation, laparoscopic excision of the ovarian fibroid (Târcoveanu et al, 2007). In all cases histological examination of the tissue is necessary to confirm the diagnosis (Hasegawa et al, 2013).

The prognosis of ovarian fibroids is usually very good. Numanoglu et al. during the analysis of the results of their study arrived in the conclusion that the Risk of Malignancy Index of ovarian fibroids is not a very helpful clinical marker, both because of false positive results and the marker's low sensitivity. Further research with a greater number of studied patients seem necessary, in order to define the importance of Risk of Malignancy Index in the preoperative detection of malignancy (Numanoglu et al, 2013).

CONCLUSIONS

Fibroid tumors of the ovaries are not common. They are

the most common tumors of the ovaries, with small chances of torsion and necrosis. Besides their rarity, ovarian fibrosis should be taken into consideration during the differential diagnosis of women with abdominal pain and presence pelvic mass. Pre-operative diagnosis is not easy. Surgical excision of the tumor is the therapy of choice that in the same time sets the diagnosis of ovarian fibrosis (Boujoual et al, 2015).

REFERENCES

- Boujoual M, Hakimi I, Kouach J, Oukabli M, Moussaoui DR, Dehayni M. Large twisted ovarian fibroma in menopausal women: a case report. *Pan Afr Med J.* 2015; 20: 322.
- Cambrozzi E, Pegas KL, Milani DM, Cruz RP, Guerra EH, Ferrari MB. Angiosarcoma arising in an ovarian fibroma: a case report. *Patholog Res Int.* 2010; 2010: 842592.
- Chang HC, Bhatt S, Dogra VS. Pearls and Pitfalls in Diagnosis of Ovarian Torsion. *Radio Graphics.* 2008; 28(5): 1355 – 1368.
- Cho YJ, Lee HS, Kim JM, Joo KY, Kim ML. Clinical characteristics and surgical management options for ovarian fibroma/fibrothecoma: a study of 97 cases. *Gynecol Obstet Invest* 2013; 76: 182 – 187.
- Daponte A, Pournaras S, Hadjichristodoulou C, Lialios G, Kallitsaris A, Maniatis AN, Messinis IE. Novel serum inflammatory markers in patients with adnexal mass who had surgery for ovarian torsion. *Fertil Steril.* 2006; 85(5): 1469 – 1472.
- Genç M, Solak A, Genç B, Sivriköz ON, Kurtulmuş S, Turan A, Sahin N, Gür EB. A diagnostic dilemma for solid ovarian masses: the clinical and radiological aspects with differential diagnosis of 23 cases. *Eur J Gynaecol Oncol.* 2015; 36(2): 186 – 191.
- Gogineni S, Sunitha C, Chelamkuri S. Extrauterine Postmenopausal fibroid with torsion. *IOSR Journal of Dental and Medical Sciences.* 2013; 5(5): 69 – 71.
- Hasegawa A, Koga K, Asada K, Wada – Hiraie O, Osuga Y, Kozuma S. Laparoscopic ovarian – sparing surgery for a young woman with an exophytic ovarian fibroma. *J Obstet Gynaecol Res* 2013; 39: 1610 – 1613.
- Jung SE, Rha SE, Lee JM, Park SY, Oh SN, Cho KS, Lee EJ, Byun JY, Hahn ST. CT and MRI Findings of Sex Cord – Stromal Tumor of the Ovary. *AJR Am J Roentgenol.* 2005; 185(1): 207 – 215.
- Liu MY, Xue HD, Jin ZY. CT findings of ovarian fibroma in 9 patients. *Zhongguo Yi Xue Ke Xue Yuan Xue Bao* 2012; 34: 104 – 108.
- Macciò A, Madeddu C, Kotsonis P, Pietrangeli M, Paoletti AM. Large twisted ovarian fibroma associated with Meigs' syndrome, abdominal pain and severe anemia treated by laparoscopic surgery. *BMC Surgery.* 2014; 14: 38.
- Mak CW, Tzeng WS, Chen CY. Computed tomography appearance of ovarian fibrothecomas with and without torsion. *Acta Radiol.* 2009; 50(5): 570 – 575.
- Mansoor NA, Jezan HS. Spectrum of ovarian tumors: Histopathological study of 218 cases. *Gulf J Oncolog.* 2015; 1(18): 64 – 70.
- Najmi Z, Mehdizadehkashi A, Kadivar M, Tamannaie Z, Chaichian S. Laparoscopic Approach to a Large Ovarian Fibroma: A Case Report. *J Reprod Infertil.* 2014; 15(1): 57 – 60.
- Nigam A, Jain S, Lal P. Twisted Ovarian Fibroma Mimicking as an Ectopic Pregnancy. *Journal of case reports.* 2013; 3(1): 64 – 67.
- Numanoglu C, Kuru O, Sakinci M, Akbayir O, Ulker V. Ovarian fibroma/fibrothecoma: retrospective cohort study shows limited value of risk of malignancy index score. *Aust N Z J Obstet Gynaecol* 2013; 53: 287 – 292.
- Paladini D, Testa A, Van Holsbeke C, Mancari R, Timmerman D, Valentin L. Imaging in gynecological disease (5): clinical and ultrasound characteristics in fibroma and fibrothecoma of the ovary. *Ultrasound Obstet Gynecol* 2009; 34: 188 – 195.
- Pirschner F, Bastos PM, Contarato GL, Bimbato AC, Filho AC. Gorlin syndrome and bilateral ovarian fibroma. *Int J Surg Case Rep* 2012; 3: 477 – 480.
- Rambocas N, Murphy D. Gynecologic implications of Gorlin – Goltz syndrome. *Int J Gynaecol Obstet* 2013; 123: 166.
- Riker D, Goba D. Ovarian mass, pleural effusion, and ascites: revisiting Meigs syndrome. *J Bronchology Intery Pulmonol* 2013; 20: 48 – 51.
- Shinagare AB, Meylaerts LJ, Laury AR, Mortelet KJ. MRI Features of Ovarian Fibroma and Fibrothecoma with Histopathologic Correlation. *AJR Am J Roentgenol.* 2012; 198(3): W296 – 303.
- Son CE, Choi JS, Lee JH, Jeon SW, Hong JH, Bae JW. Laparoscopic surgical management and clinical characteristics of ovarian fibroma. *JLSLS* 2011; 15: 16 – 20.
- Târcoveanu E, Dimofte G, Niculescu D, Vasilescu A, Moldovanu R, Ferariu D, Marcovici I. Ovarian fibroma in the era of laparoscopic surgery: a general surgeon's experience. *Acta Chir Belg.* 2007; 107(6): 664 – 669.
- Taskin MI, Ozturk E, Yildirim F, Ozdemir N, Inceboz U. Primary ovarian leiomyoma: a case report. *Int J Surg Case Rep.* 2014; 5(10): 665 – 668.
- Yazdani S, Alijanpoor A, Sharbatdaran M, Bouzari Z, Abedisamakoosh M, Lakaieandi F, Mohammadpour M. Meigs' syndrome with elevated serum CA125 in a case of ovarian fibroma /thecoma. *Caspian Journal of Internal Medicine.* 2014; 5(1): 43 – 44.
- Yen P, Khong K, Lamba R, Corwin MT, Gerscovich EO. Ovarian fibromas and fibrothecomas: sonographic correlation with computed tomography and magnetic resonance imaging: a 5 – year single-institution experience. *J Ultrasound Med.* 2013; 32(1): 13 – 18.
- Young RH, Scully RE. Ovarian stromal tumors with minor sex cord elements: a report of seven cases. *Int J Gynecol Pathol* 1983; 2: 227 – 234.
- Zhang Z, Wu Y, Gao J. CT diagnosis in the thecoma – fibroma group of the ovarian stromal tumors. *Cell Biochem Biophys.* 2015; 71(2): 937 – 943.